

Peritoneum

# Abdominal complications of peritonitis

BY: DR. AHMED MODHER KHALAF

Adhesional small bowel obstruction ■

Paralytic ileus ■

Residual or recurrent abscess ■

Portal pyaemia/liver ■

## **Acute intestinal obstruction due to peritoneal adhesions**

This usually gives central colicky abdominal pain with evidence of small bowel gas and fluid levels sometimes confined to the proximal intestine on X-ray. Bowel sounds are increased. It is more common with localised peritonitis. It is essential to .distinguish this from paralytic ileus

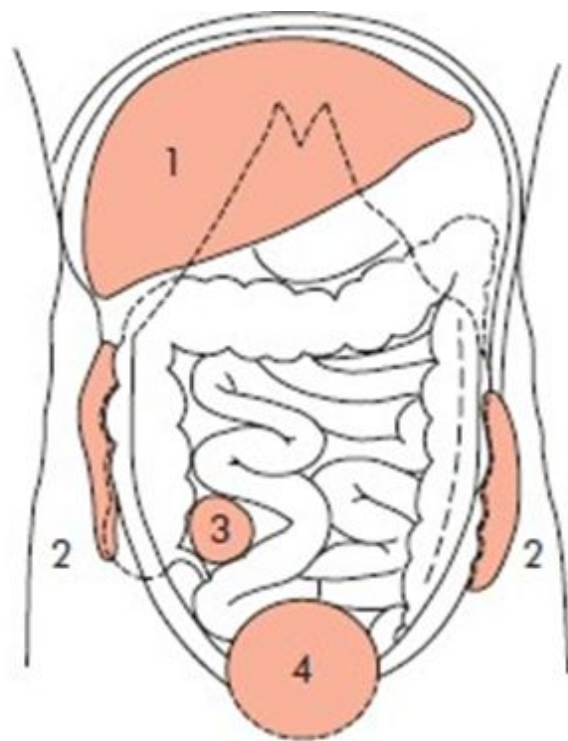
## **Paralytic ileus**

There is usually little pain and gas-filled loops with fluid levels are seen distributed throughout the small and large intestines on abdominal X-ray. In paralytic ileus, .bowel sounds are reduced or absent

## Abscesses

Abscess formation following local or diffuse peritonitis usually occupies one of the situations shown in the figure below. The symptoms and signs of a purulent collection may be very vague and consist of nothing more than lassitude, anorexia and failure to thrive; pyrexia (often low-grade), tachycardia, leucocytosis and localised tenderness are also common. Later on a palpable mass may develop. When palpable an intraperitoneal abscess should be monitored by marking out its limitations on the abdominal wall, and meticulous daily examination

More commonly its course is monitored by repeat ultrasound or CT scanning. In the majority of cases with the aid of antibiotic treatment, the abscess or mass becomes smaller and smaller, and finally is undetectable. In others, the abscess fails to resolve, or becomes larger, in which event it must be drained. In many situations, by waiting for a few days the abscess becomes adherent to the abdominal wall, so that it can be drained without opening the general peritoneal cavity; If facilities are available ultrasound or CT-guided drainage may avoid further operation. Open drainage of an intraperitoneal collection should be carried out by cautious blunt finger exploration to minimise .the risk of an intestinal fistula



Common situations for residual abscesses: (1) sub-phrenic; (2) paracolic; (3) right iliac fossa; (4) pelvic.

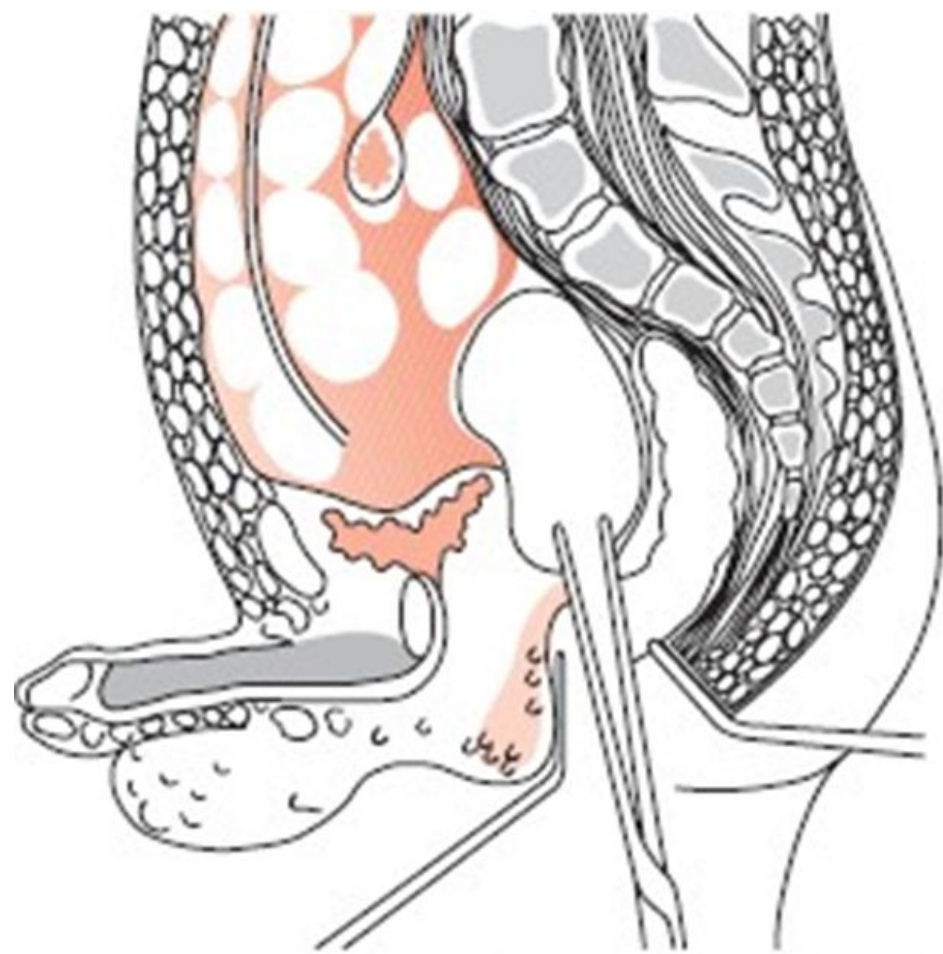
## **Pelvic abscess**

The pelvis is the commonest site of an intraperitoneal abscess because the vermiform appendix is often pelvic in position and also the Fallopian tubes are frequent sites of infection. A pelvic abscess can also occur as a sequel to any case of diffuse peritonitis and is a common sequel of anastomotic leakage following large bowel and rectal surgery. Pus can accumulate in this area without serious constitutional disturbance and unless the patient is examined carefully from day to day, such abscesses may attain considerable proportions before being recognised. The most characteristic symptoms of a pelvic abscess are diarrhoea and the passage of mucus in the stools

The passage of mucus, occurring for the first time in a patient who has, or is recovering from, peritonitis, is pathognomonic of pelvic abscess. Rectal examination reveals a bulging of the anterior rectal wall which, when the abscess is ripe, becomes softly .cystic

Left to nature, a proportion of these abscesses burst into the rectum, after which the patient nearly always recovers rapidly. If this possible happy termination does not readily occur the abscess should be drained. In women vaginal drainage through the posterior fornix is often chosen. In other cases, where the abscess is definitely pointing into the rectum, rectal drainage (Fig. below) is employed. If any uncertainty exists, the presence of pus can be confirmed by ultrasound or CT scanning or by an aspirating needle introduced through the rectum or abdominal wall into the swelling. Laparotomy is almost never necessary. Rectal drainage of a pelvic abscess is far preferable to .suprapubic drainage, which risks exposing the general peritoneal cavity to infection Drainage tubes can also be inserted percutaneously or via the vagina or rectum under .radiological (ultrasonic or CT) guidance (Figure below)





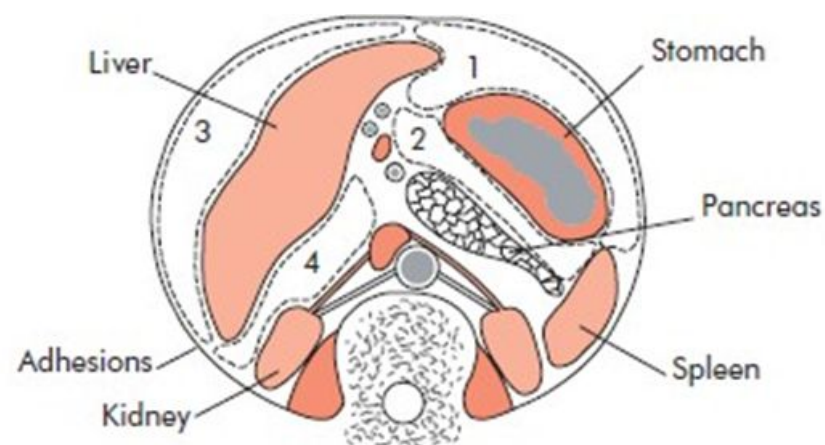
Opening a pelvic abscess into the rectum.

## Subphrenic abscess

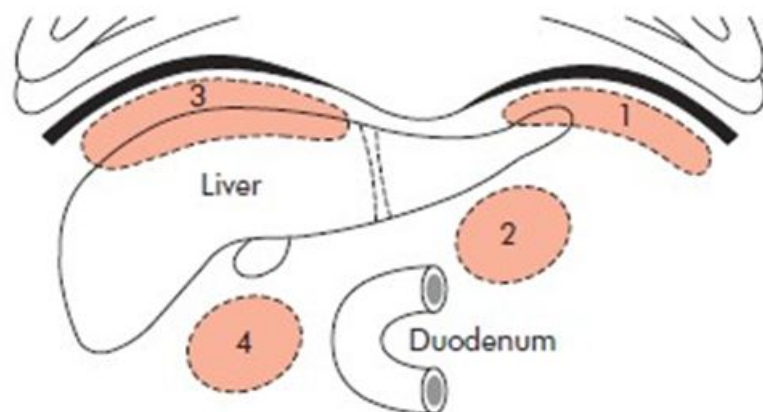
### Anatomy

The complicated arrangement of the peritoneum results in the formation of **four intraperitoneal** and **three extraperitoneal** spaces in which pus may collect. Three of these spaces are on either side of the body, and one is approximately in the midline

.(Figs below)



**Figure 58.8** Intrapertoneal abscesses on transverse section. (1) The left subphrenic space; (2) left subhepatic space/lesser sac; (3) right subphrenic space; (4) right subhepatic space.



**Figure 58.9** Intrapertoneal abscesses on sagittal section. (1) Left subphrenic; (2) left subhepatic/lesser sac; (3) right subphrenic; (4) right subhepatic.

## Intraperitoneal abscesses

**Left superior (anterior) intraperitoneal ('left subphrenic')** is bounded above by the diaphragm, and behind by the left triangular ligament and the left lobe of the liver, the gastrohepatic omentum and anterior surface of the stomach. To the right is the falciform ligament and to the left the spleen, gastrosplenic omentum and diaphragm. The common cause of an abscess here is an operation on the stomach, the tail of the pancreas, the spleen or the splenic flexure of the colon

**Left inferior (posterior) intraperitoneal ('left subhepatic')** is another name for the 'lesser' sac. The commonest cause of infection here is complicated acute pancreatitis. In practice a perforated gastric ulcer rarely causes a collection here because the potential space is .obliterated by adhesions

**Right superior (anterior) intraperitoneal ('right subphrenic')** lies between the right lobe of the liver and the diaphragm. It is limited posteriorly by the anterior layer of the coronary and the right triangular ligaments, and to the left by the falciform ligament. Common causes here are perforating cholecystitis, a perforated duodenal ulcer, a duodenal cap 'blow out' following gastrectomy and appendicitis

**Right inferior (posterior) intraperitoneal ('right subhepatic')** lies transversely beneath the right lobe of the liver in Rutherford Morison's pouch. It is bounded on the right by the right lobe of the liver and the diaphragm. To the left is situated the foramen of Winslow and below this lies the duodenum. In front are the liver and the gall bladder, and behind, the upper part of the right kidney and diaphragm. The space is bounded above by the liver, and below by the transverse colon and hepatic flexure. It is the deepest space of the four and the commonest site of a subphrenic abscess which usually arises from appendicitis, cholecystitis, a perforated duodenal ulcer or following upper abdominal surgery

## Extraperitoneal abscesses

:There are three of these

**Right and left extra peritoneal** which are terms given to perinephric ; abscesses

**Midline extraperitoneal** which is another name for the 'bare' area of the liver which may develop an abscess in amoebic hepatitis (the .commonest cause) or a pyogenic liver abscess



## **Clinical features**

The symptoms and signs of subphrenic infection are frequently nonspecific, and it is well to remember the aphorism, 'pus somewhere, pus nowhere else, pus under .'.diaphragm

### **Summary of clinical features of an abdominal/pelvic abscess**

Malaise ■

Sweats with or without rigors ■

Abdominal/pelvic (with or without shoulder tip) pain ■

Anorexia and weight loss ■

Symptoms from local irritation, e.g. hiccoughs (subphrenic), diarrhoea and mucus ■  
(pelvic)

Swinging pyrexia ■

Localised abdominal tenderness/mass ■

## Symptoms

A common history is that when some infective focus in the abdominal cavity has been dealt with, the condition of the patient improves temporarily, but after an interval of a few days or weeks, symptoms of toxæmia reappear. The condition of the patient steadily, and often rapidly, deteriorates. Sweating, wasting and anorexia are present. There is sometimes epigastric fullness and pain, or pain in the shoulder on the affected side, owing to irritation of sensory fibres in the phrenic nerve, referred along the descending branches of the cervical plexus. Persistent hiccup may be a presenting symptom

## Signs

A swinging pyrexia is usually present, unless antibiotics or drugs (steroids) have interfered. If the abscess is anterior, abdominal examination will reveal some tenderness, rigidity or even a palpable swelling. Sometimes the liver is displaced downwards, but more often it is fixed by adhesions. Examination of the chest is important, and in the majority of cases collapse of the lung or evidence of basal effusion .or empyema is to be found

## Investigations

.A number of these may be helpful as follows

.Blood count usually shows a leucocytosis (1

A plain radiograph sometimes demonstrates the presence of gas or a pleural (2  
effusion. On screening, the diaphragm is often seen to be elevated (so-called  
.tented' diaphragm) and its movements impaired'

Ultrasound or CT scanning is the investigation of choice and permits early (3  
.detection of subphrenic collections

Radiolabelled white cell scanning may occasionally prove helpful when other (4  
.imaging techniques have failed

**Differential diagnosis.** Pyelonephritis, amoebic abscess, pulmonary collapse and pleural empyema give rise to most of the diagnostic .difficulties

## **Treatment of abdominal abscess**

The clinical course of suspected cases is watched, and blood and imaging ,investigations are made at suitable intervals. If suppuration seems probable intervention is indicated. If skilled help is available it is possible to insert a percutaneous drainage tube under ultrasound or CT control. The same tube can be used to instil antibiotic solutions or irrigate the abscess cavity. To pass an aspirating needle at the bedside through the pleura and diaphragm invites potentially catastrophic spread of the .infection into the pleural cavity

If an operative approach is necessary and a swelling can be detected in the subcostal region or in the loin, an incision is made over the site of maximum tenderness, or over any area where oedema or redness is discovered. The parietes usually form part of the abscess wall so that contamination of the general peritoneal cavity is unlikely. If no swelling is apparent, the subphrenic spaces should be explored either by an anterior subcostal approach or from behind after removal of the outer part of the 12th rib according to the position of abscess on imaging. With the posterior approach the pleura must not be opened and after the fibres of the diaphragm have been separated a finger is inserted beneath the diaphragm so as to explore the adjacent area. The aim with all techniques of drainage is to avoid dissemination of pus into the peritoneal or pleural cavities

When the cavity is reached, all of the fibrinous loculi must be broken down with the finger and one or two drains or drainage tubes must be fully inserted. These drains are withdrawn gradually during the next 10 days and the closure of the cavity is checked by .sinograms or scanning. The appropriate antibiotics are also given