

Carcinoma of the breast

Dr.mohamad habash •

Aetiological factors

Biographical factors: it is common in western world & less in the developing countries. It is rare in Japan.

Age, CA breast is extremely rare below 20 yrs.

The incidence increase with age & at age of 90 yrs., more than 20% affected.

Gender. In male the incidence is only $< 0.5\%$.

Genetic. It is more common in females with positive family history for breast CA than in the general population. Breast CA due to specific mutation account for **5-10%** of cause. Presence of mutation in BRCA1 & BRCA2 increases the risk for CA breast by 60%. The presence of breast CA in the mother or sister increases the risk by 2.3 times while the presence of the disease in both the mother & sister increase the risk by 14 times.

Diet. Obesity & high intake of saturated fat are associated with increased risk. *In obese, there is increase conversion of oestrogen into oestradiol in the body fat.*

Endocrine factors

CA breast is common in nulliparous women, females with early menarche & late menopause.

The following is protective against breast CA.

...Having the first child at an early age.

...Breast feeding

...Late menarche & early menopause.

The **role of oral contraceptive pills** (exogenous estrogen) & hormone replacement therapy in the development of CA breast is more controversial.

Pre cancerous lesions include

..Moderate or florid epithelial hyperplasia & duct papilloma increase the risk by 1.5-2 times.

.. A typical epithelial hyperplasia increases the risk by 2-5 times.

.. Lobular or ductal carcinoma in situ increases the risk by 5-10 times.

.. Previous affection with breast CA.

Patient with breast CA in one side, have an increased risk to develop carcinoma of the other breast.

Previous radiation

This was considered to be of historical interest, as the majority of women exposed to the atomic bombs at Hiroshima and Nagasaki are died .

Pathology

- ... Breast cancer may arise from the epithelium of the duct system anywhere from the nipple end of major lactiferous ducts to the terminal duct unit which is in the breast lobule.
- ... It may be entirely in situ or may be invasive cancer.
- ... The degree of differentiation of the tumour is usually described by three grades — well differentiated, moderately or poorly differentiated.
- ... **Ductal carcinoma** is the most common variant, but **lobular carcinoma** occurs in up to 15 per cent of cases.
- ... **Rarer histological variants**, usually carrying a better prognosis, include **colloid carcinoma** whose cells produce abundant mucin, **medullary carcinoma** with solid sheets of large cells often associated with a marked lymphocytic reaction and **tubular carcinoma**.
- ... Invasive lobular carcinoma is commonly multi-focal and/or bilateral.

...Inflammatory carcinoma is a fortunately **rare, highly aggressive** cancer which presents as a painful, swollen breast, which is warm with cutaneous oedema. This is due to blockage of the subdermal lymphatics with carcinoma cells. Inflammatory cancer usually involves at least one-third of the breast and may mimic a breast abscess. A biopsy will confirm the diagnosis and show undifferentiated carcinoma cells.

...In situ carcinoma *is preinvasive cancer which has not breached the epithelial basement membrane*. This was previously a rare, usually asymptomatic finding in breast biopsy specimens but is becoming increasingly common owing to the advent of mammographic screening — it accounts for 20 per cent of cancers detected by screening. In situ carcinoma may be ductal (**DCIS**) or lobular (**LCIS**), the latter often multifocal and bilateral. Both are markers for the later development of invasive cancer which will go on to develop in at least 20 percent of cases.

Paget's disease of the nipple

Paget's disease of the nipple is a superficial manifestation of an underlying breast carcinoma. It presents as an eczema-like condition of the nipple and areola which persists in spite of local treatment. The nipple is eroded slowly and eventually disappears. If left, the underlying carcinoma will sooner or later become clinically evident. Thus nipple eczema should be biopsied if there is any doubt about its cause.

After the paget's disease of the nipple has been confirmed with punch biopsy of the nipple areola complex, the traditional surgical treatment is mastectomy with or without axillary dissection.

Spread of mammary carcinoma

1. Local spread.

The tumour increases in size and invades other portions of the breast. It tends to involve the skin and to penetrate the pectoral muscles, and even the chest wall.

2. Lymphatic metastasis

Occurs primarily to the axillary lymph nodes and to the internal mammary chain of lymph nodes. In advanced disease there may be involvement of supraclavicular nodes and of any contra lateral lymph nodes.

3. Spread by the bloodstream.

It is by this route that skeletal metastases occur (in order of frequency) in the lumbar vertebrae, femur, thoracic vertebrae, rib and skull; they are generally osteolytic. Metastases may also occur in the liver, lung and brain, and occasionally the adrenal glands and ovaries.

Clinical presentation

- While any portion of the breast, including the axillary tail, may be involved, breast cancer commences **most frequently in the upper, outer quadrant**.
- Most breast cancers will present as *a hard lump*, which may be associated with *indrawing of the nipple*.
- As the disease advances locally there may be skin involvement with *peau d'orange* or *frank ulceration and fixation to the chest wall*. This is described as *cancer-encuirasse*.
- About 5 per cent of breast cancers will present with either *locally advanced disease or symptoms of metastatic disease*.
- Rarely present as a pain

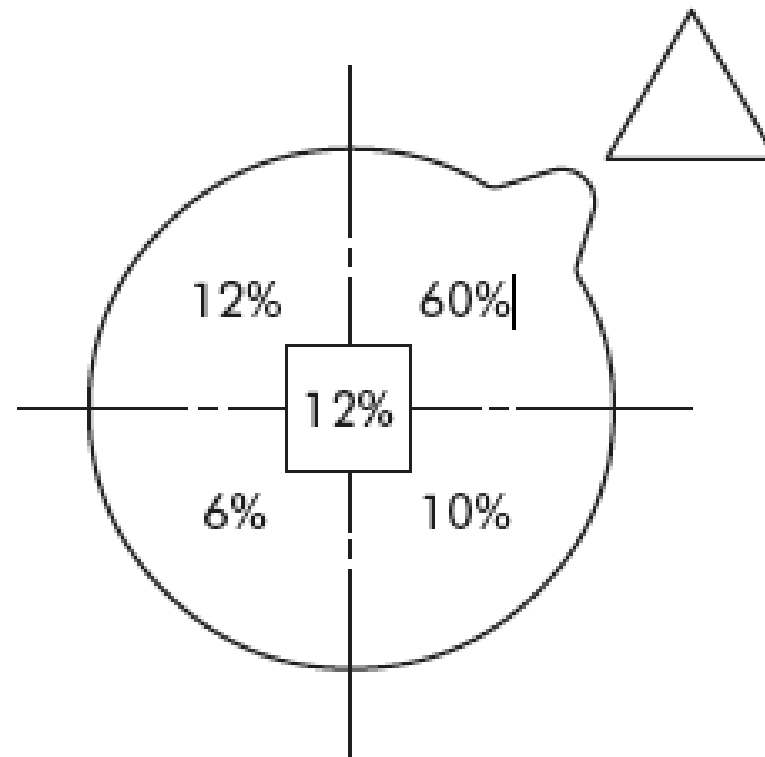


Figure 53.23 The relationship of carcinoma of the breast to the quadrants of the breast.

Staging evaluation

The full extent of the disease can be ascertained. In patient with *cancer-encuirasse* this will include a careful clinical examination, chest X-ray, serum alkaline phosphatase and gamma glutamine transaminase (GGT), with liver ultrasound if these are abnormal, and an isotope bone scan. **This is important for both prognosis and treatment** — a patient with widespread visceral metastases may obtain an increased length and quality of survival from systemic hormone or chemotherapy, but she is not likely to benefit from surgery as she will die from her metastases before local disease becomes a problem.

In contrast, patients with relatively *small* (less than 5 cm in diameter) tumours confined to the breast and ipsilateral lymph nodes rarely need staging beyond a good clinical examination as the pick-up rate for distant metastases is so low.

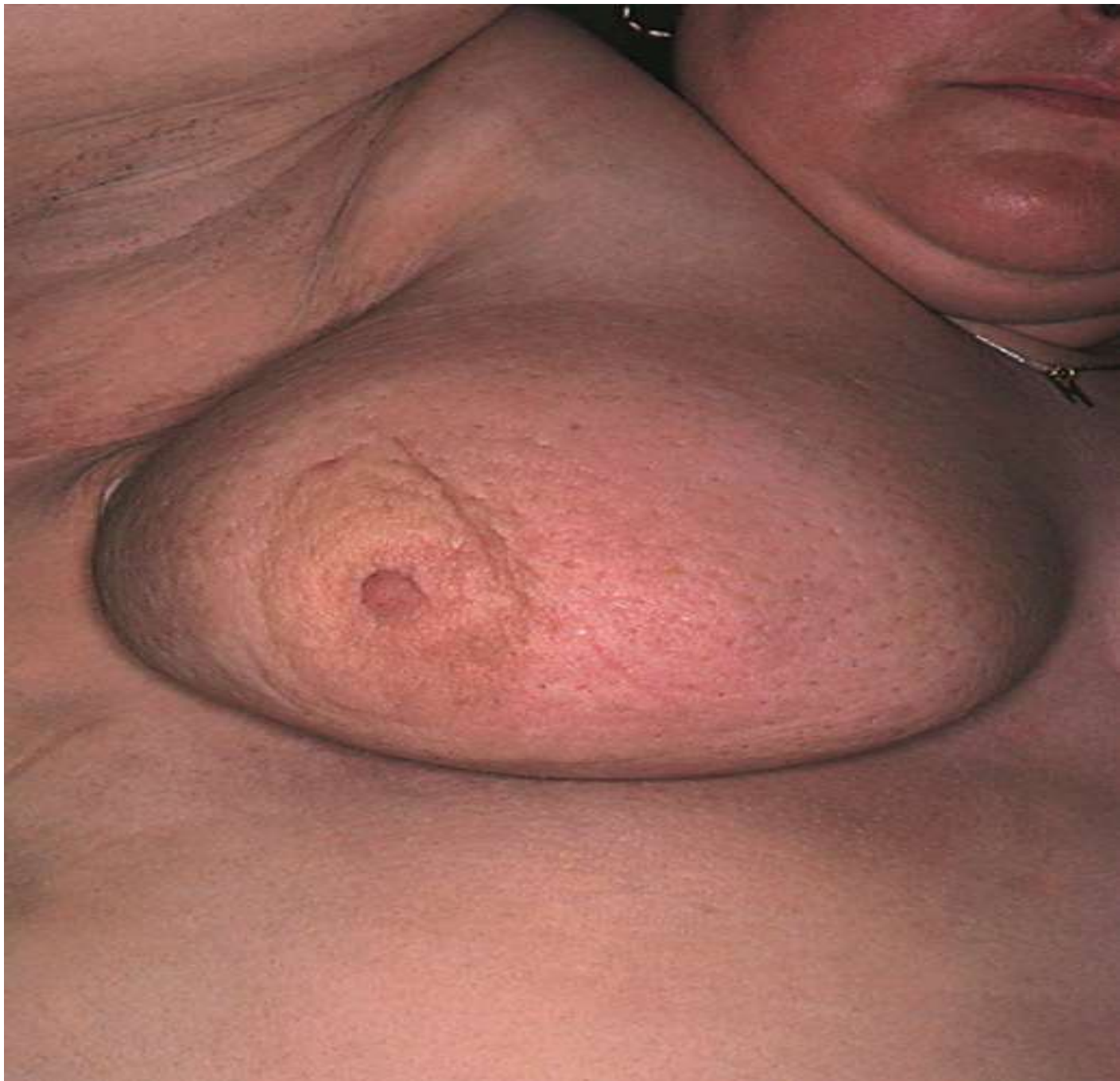Phenomena resulting from lymphatic obstruction in advanced breast cancer

- ***Peau d'orange*** is due to cutaneous lymphatic oedema. Where the infiltrated skin is tethered by the sweat ducts it cannot swell, leading to an appearance like orange skin.
- ***Late oedema of the arm*** is a troublesome complication of breast cancer treatment fortunately seen less often now that *radical axillary dissection* and *radiotherapy* are rarely combined. It does however occasionally still occur after either modality of treatment alone and appears anytime from months to years after treatment. There is usually no precipitating cause but *recurrent tumour* should be excluded as neoplastic infiltration of the axilla can cause arm swelling due to *both lymphatic and venous blockage*.

Treatment

An oedematous limb is susceptible to bacterial infections following quite minor trauma, and these require vigorous antibiotic treatment.

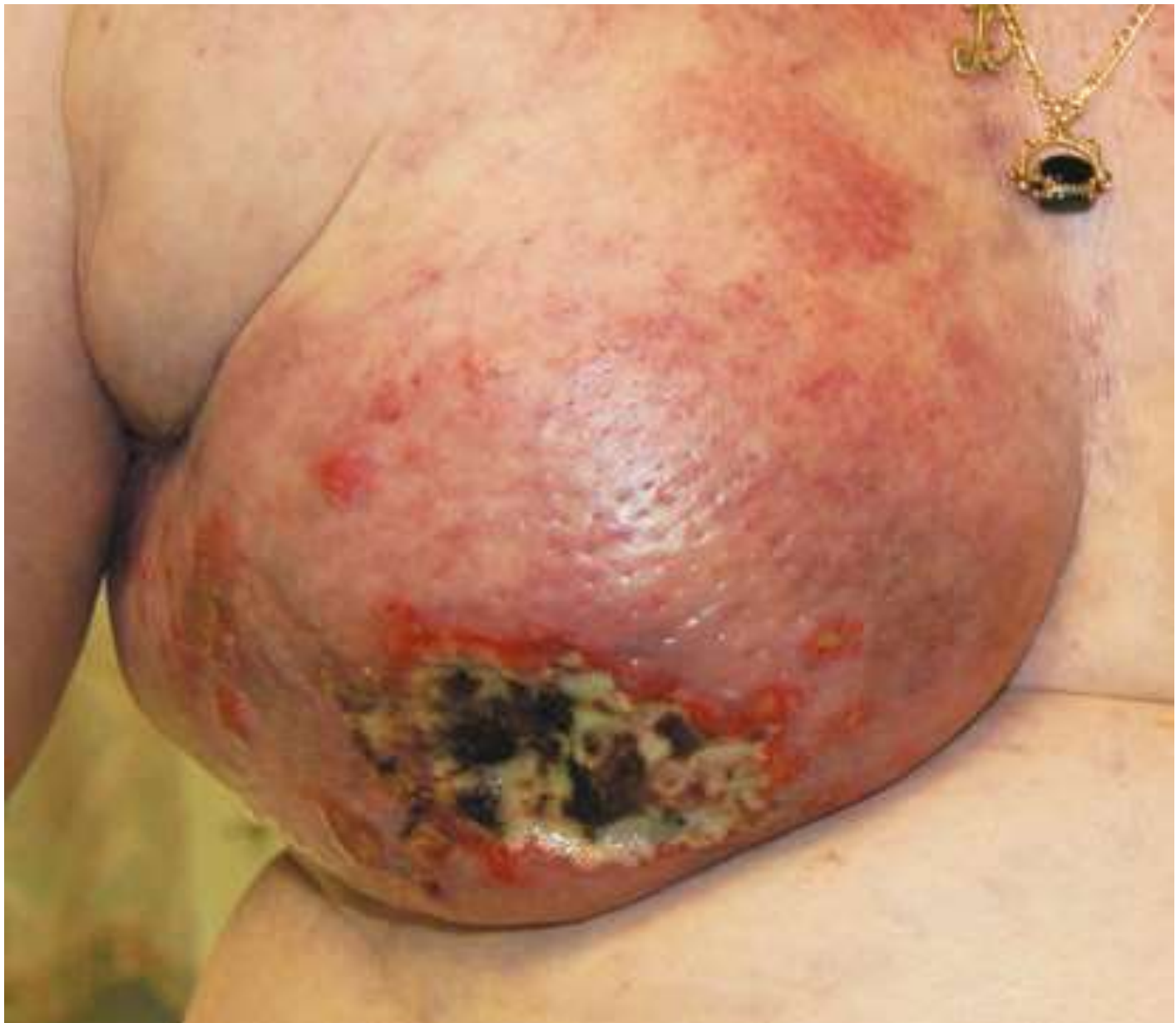Treatment of late oedema is difficult but limb elevation, elastic arm stockings and pneumatic compression devices can be useful.



• **Cancer-en-cuirasse**

The skin of the chest is infiltrated with carcinoma and has been likened to a coat. It may be associated with a grossly swollen arm. **This usually occurs in cases with local recurrence after mastectomy, and occasionally is seen to follow the distribution of irradiation to the chest wall.** The condition may respond to palliative systemic treatment but prognosis in terms of survival is poor.

• **Lymphangiosarcoma** is a rare complication of lymphoedema with an onset many years following the original treatment. It takes the form of multiple subcutaneous nodules in the upper limb. The prognosis is poor but some cases respond to cytotoxic therapy or irradiation.



Staging

There are two traditional systems of classification for breast carcinoma which predominantly rely on clinical staging of the disease. These are the Manchester system and the International Union Against Cancer TNM (tumour, nodes, metastases) staging system.

Prognosis of breast cancer

The best indicators of prognosis in CA breast are still the

1. Tumour size and
2. Lymph node status.

But some large tumors remain confined to the breast for decades and some small tumours are incurable at the time of diagnosis.

So the prognosis of CA breast, depend not on it's chronologic age but on it's invasive and metastatic potential.

•Tumour factors that affect the prognosis are:

- 1.Histological grade of the tumour (nuclear grade).
- 2.Hormone receptor status.
- 3.Measures of tumour proliferation e.g S. phase fraction and thymidine labeling index.
- 4.Growth factor analysis.
- 5.Oncogen or oncogen product measurements.
- 6.Nodal status.
- 7.Tumour size.
- 8.Lymphatic/ vascular invasion.
- 9.Extensive intraductal component.

•Host factors that affect the prognosis in CA breast:

** Age *menopausal Status * family HX of CA breast * Previous CA breast * presence of immunosuppression * nutritional history of the patient * prior chemo therapy * prior radiotherapy.*

Treatment of the breast cancer

Treatment will largely depend upon clinical stage of the disease at presentation including not only classical TNM staging but often other tumour characteristics such as tumour grade.

Treatment of early breast cancer

The aims of treatment are:

- 1.** 'Cure': possible in some patients but recurrence up to 20 years after initial treatment is not uncommon;
- 2.** Control of local disease in the breast and axilla;
- 3.** Conservation of local form and function;
- 4.** Prevention or delay of the occurrence of distant metastases.

Local treatment of early breast cancer

Local control is achieved through surgery and/or radiotherapy.

Surgery

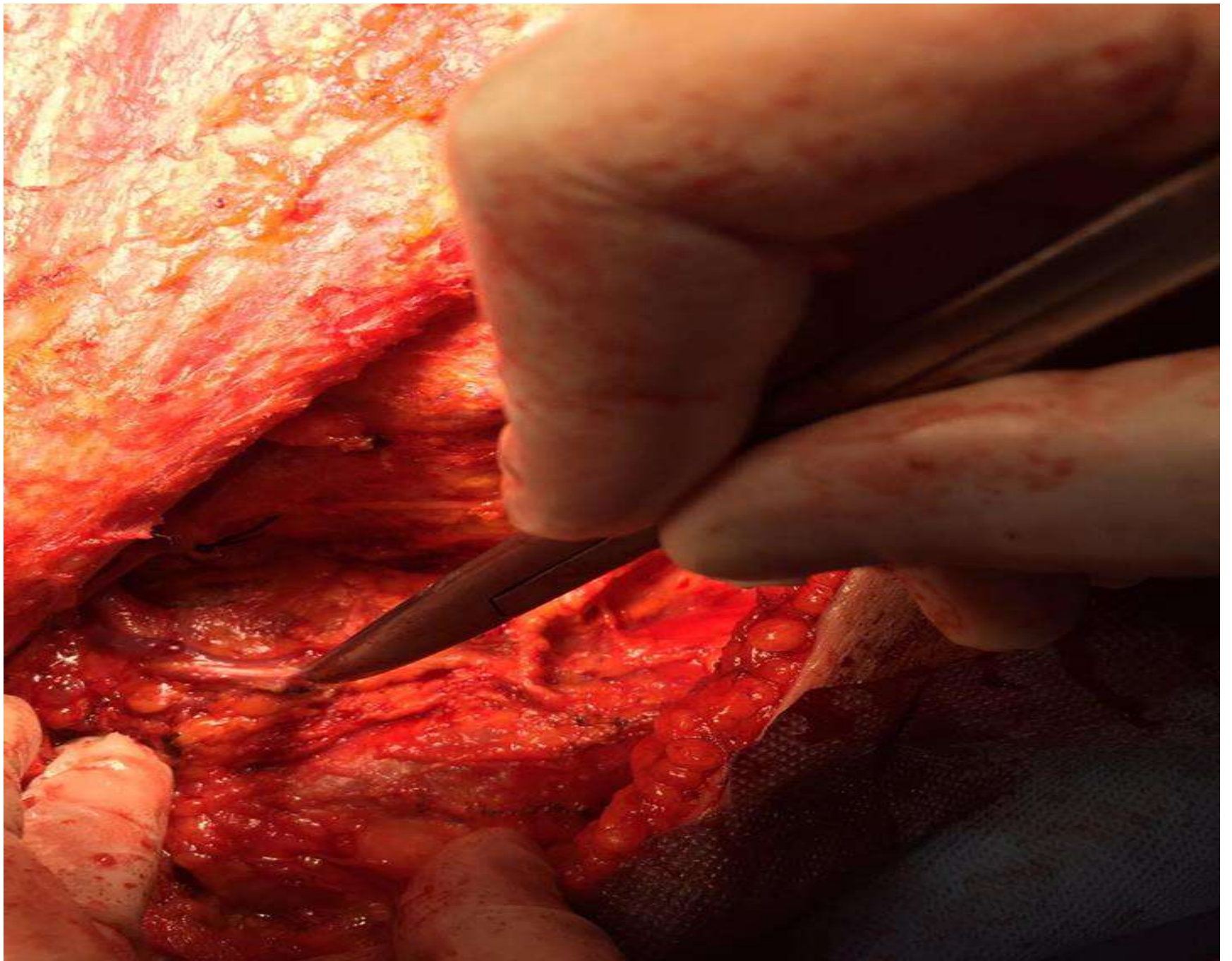
Surgery still has a central role to play in the management of breast cancer *Patey' mastectomy*

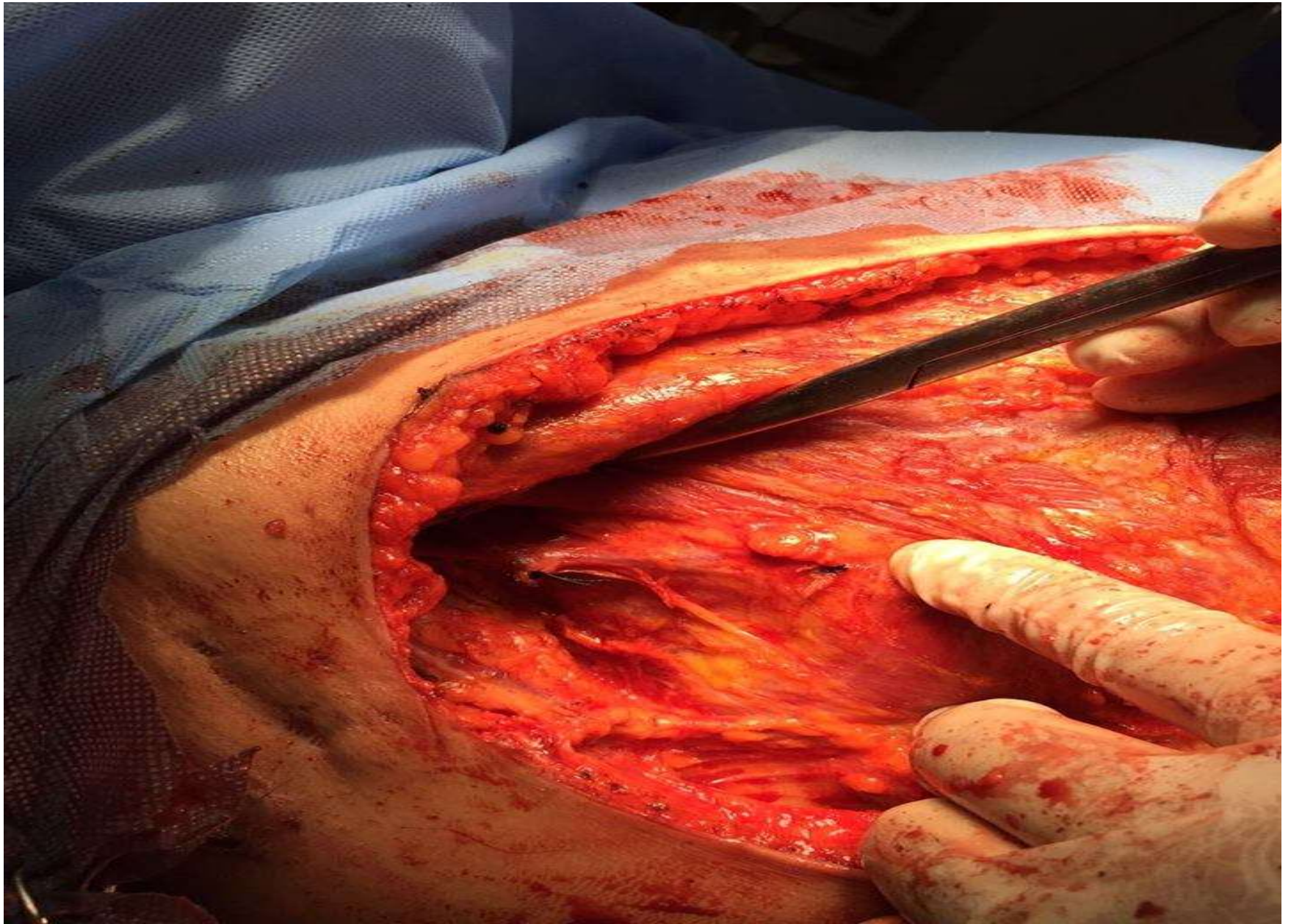
The breast and associated structures are dissected en bloc and the excised mass is composed of:

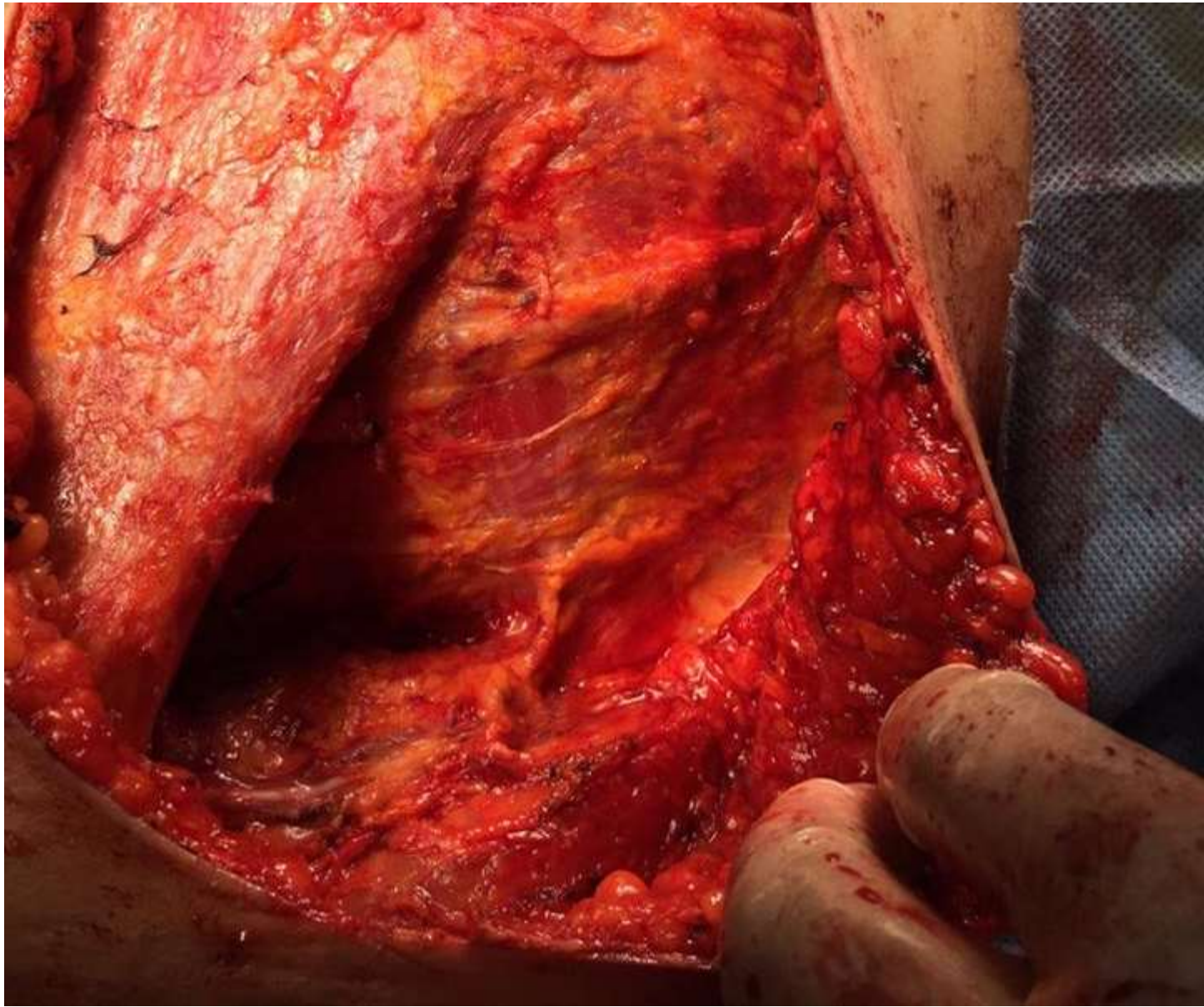
- The whole breast;
- A large portion of skin, the centre of which overlies the tumour, but always includes the nipple;
- All of the fat, fascia and lymph nodes of the axilla. The pectoralis minor muscle is either divided or removed to gain access to the upper two-thirds of the axilla. The axillary vein and nerves to serratus anterior and latissimus dorsi should be preserved.

The wound is drained using a wide-bore suction tube.

Early mobilisation of the arm is encouraged and physiotherapy helps normal function to return very quickly







Currently, mastectomy with assessment of the axillary lymph nodes and breast conservation (lumpectomy with axillary lymph node dissection through separate incision & radio therapy) are both considered equivalent treatment for stages I & II.

• Axillary lymphadenopathy or metastatic disease in sentinel axillary lymph nodes necessitates an axillary dissection for lymph nodes.

Contraindications for conservative surgery are:

- ❖ Central disease.
- ❖ Multifocal.
- ❖ Recurrent disease.
- ❖ Larger mass in comparison to the size of the breast
- ❖ Prior radio therapy to the breast or the chest wall
- ❖ Involved surgical margins or unknown margin status following re excision.
- ❖ Scleroderma or other connective tissues disease.

Adjuvant chemotherapy for early invasive breast CA is considered for:

1. All node positive CA.
2. All cancers that are larger than one cm size.
3. For node negative cancers larger than 0.5cm size when adverse prognostic features is present which include;
 1. Blood or lymphatic vessel invasion.
 2. High nuclear grade.
 3. High histological grade.
 4. HER2/ neu over expression, and;
 5. Negative hormone receptor status.

Tamoxifen therapy is considered for hormone receptor positive women.

HER/2 neu overexpression is determined for all newly diagnosed patients with breast CA and may be used to:

- 1.** Provide prognostic information in patient with node negative breast CA.
- 2.** Predict the relative efficacy of various chemotherapy regimens.
- 3.** Predict the benefit from herceptin in women with metastatic or recurrent breast CA.

Treatment options in advanced loco-regional breast CA (stage IIIa, IIIb)

- Those women have advanced loco regional breast CA, but have no clinically detected distant metastasis.
- In an effort to provide optimal loco regional disease free survival & distant disease-free survival for those women, surgery is integrated with radio therapy & chemo therapy.
- Stage III patients are divided into those who have operable disease and those who have non operable disease.

Patients with operable stage IIIa disease, require modified radical mastectomy followed by adjuvant chemotherapy followed by adjuvant radio therapy.

Patients with non-operable stage IIIa and for stage IIIb, neoadjuvant chemotherapy is used to decrease the locoregional cancer burden & may permit subsequent surgery to establish locoregional control. In this setting, surgery is followed by adjuvant chemotherapy & adjuvant radio therapy.

Treatment of a female with distant metastasis stage IV breast CA

Treatment for stage IV breast is not curative, but may prolong survival. **Hormonal therapy that is associated with minimal toxicity is preferred to cytotoxic chemotherapy.**

• The appropriate candidates for initial hormonal therapy include:

- ❖ Female with hormone receptor positive CA.
- ❖ Female with bone or soft tissue metastases only.
- ❖ Female with limited and asymptomatic visceral metastases.

• Systemic chemo therapy is indicated for:

1. Female with hormone receptor negative CA.
2. Symptomatic visceral metastases.
3. Hormone refractory metastases.

- For premenopausal & postmenopausal female with stage 4 disease, an anti estrogen with tamoxifen is the preferred initial treatment.

In women with previous antiestrogen exposure the recommended **second line hormone therapy is as follow:**

1. For postmenopausal women give aromatase inhibitor as anastrozole.

2. For premenopausal women give progestins, androgens, high dose estrogen or Oophorectomy (medical, surgical or radio ablative).

1. Biphosphonate given in addition to women with bone metastases.

- Radiotherapy for painful bony deposits and internal fixation for pathological fracture

Radio therapy is indicated in the following:

- Extensive local disease with infiltration of the chest wall.
- High grade tumour.
- Large tumour.
- Heavily node positive.
- Extensive lymphovascular invasion.
- Following conservative treatment to reduce the incidence of local recurrence
- Following mastectomy in stage 3 to reduce the incidence of local recurrence

Screening for breast cancer

It is achieved by exposing the breast to low voltage, high amperage X-ray. The dose is usually 0.1 centigray.

Screening mammography is used to detect unexpected breast CA in asymptomatic women, so it supplement history & clinical examination.

With screening mammography. Two views of the breast are obtained, the craniocaudal view & the mediolateral oblique view. Screening program could detect tumour before they come to the patients notice and this may reduce mortality from breast CA.

Breast screening by mammography over the age of 50 yrs will reduce cause specific mortality by up to 30%.

The national health center launched a program of 3 yearly mammographic screening for females between the ages of 50 & 64 years.

- Benefits of screening mammography:
 - ❖ Avoid expensive & toxic treatment of advanced CA.
 - ❖ Extra years of productivity.
 - ❖ Reassurance if the screening is negative.
 - ❖ Life years gained because more curable early CA detected.
- Disadvantages are:
 - ❖ Cost of additional cases treated.
 - ❖ Morbidity of the test.
 - ❖ Over diagnosis e.g. ductal carcinoma insitu.
 - ❖ Anxiety if the screening is positive.
 - ❖ False reassurance for false negative results.

• Specific mammographic features that suggest a diagnosis of breast CA include:

- ❖ Solid mass with or without stellate features.

- ❖ Asymmetric thickening of the breast tissue.

- ❖ Clustered micro calcification.

- ❖ The presence of fine stippled (calcification) calcium in and around suspicious lesion is suggestive of breast CA.

LCIS:

Because LCIS is considered as a marker for increased risk rather than an inevitable precursor of invasive disease, the current treatment of lobular carcinoma in situ is observation with or without tamoxifen.

LCIS is not invasive disease in the lobules or the terminal ducts. The risk of developing invasive CA which is usually infiltrative ductal carcinoma is **1% per year** & it is usually bilateral.

- The goal of treatment in LCIS is to prevent or detect at an early stage, the invasive CA that subsequently develop in 25-35% of cases.
- There is no benefit to excise LCIS as the disease diffusely involves both breasts & the risk of invasive CA is equal for both breasts.

The use of tamoxifen as risk reduction strategy should be considered in women with the diagnosis of LCIS.

If tamoxifen is contraindicated or if the patient is unable or unwilling to comply with close follow up, *bilateral prophylactic mastectomy* with or without reconstruction is also an option in patient with strong family history.

DCIS:

It also called intraductal carcinoma. It carry high risk to develop into invasive CA.It occur in both male & female. Histologically, it is characterized by proliferation of the epithelia that line the minor ducts, causing papillary growth with in the duct Lumina. The growths then will undergo necrosis. **Calcium deposits occur in areas of necrosis & are a common mammographic feature.**

Treatment of DCIS:

- If wide spread (two or more quadrants) mastectomy is required.
- If limited disease, lumpectomy & radio therapy is required.
- If low grade DCIS of the solid cribriform or papillary subtypes which is < 0.5cm in diameter, lumpectomy alone is enough.

Staining for estrogen and progesterone receptors is now considered routine as their presence will indicate the use of adjuvant hormonal therapy with tamoxifen.

Indeed, adjuvant tamoxifen therapy is considered for all DCIS patients. Patients treated with lumpectomy & radio therapy has the same mortality but higher recurrence rate than if treated by mastectomy.

How you manage breast CA in pregnant female

The treatment of CA breast in pregnant female is the same for non pregnant female with some exceptions:

- ❖ Radiotherapy should be avoided during pregnancy making mastectomy more frequent option than breast conservative surgery.
- ❖ Chemotherapy should be avoided during the first trimester but safe subsequently.
- ❖ Most tumours are hormone receptor negative and so hormone therapy which is potentially teratogenic is not required.

Becoming pregnant subsequent to the diagnosis of breast CA appear not to alter the likely outcome but if the tumour diagnosed in female, she **is advice to wait 2 years to be pregnant** as it is within this time, that recurrence most often occur.

- The treatment of stage I and II lesions during the first trimester should be with modified radical mastectomy as it eliminates the need for post operative radio therapy or chemo therapy, neither of which should be offered in the first trimester.

Patients with stage I and II lesions presenting in the second trimester can again be offered modified radical mastectomy. Another option is to offer breast conservative surgery followed immediately by chemotherapy and postpartum irradiation.

Patients should be advised to avoid pregnancy for 2 years following treatment of stage I and II CA, and for 5 years for stage III and to avoid pregnancy for stage IV.

Females should also avoid breast feeding during chemotherapy.

Termination of pregnancy has not been shown to increase survival.

Carcinoma of the male breast

Carcinoma of the male breast accounts for **less than 2 per cent** of all cases of breast cancer. The known **predisposing causes** include **gynaecomastia** and **excess endogenous or exogenous oestrogen**. As in the female it tends to present as a lump and is most commonly an infiltrating ductal carcinoma.

Treatment

Stage for stage the treatment is the same as for carcinoma in the female and prognosis depends upon stage at presentation. Adequate local excision, because of the small size of the breast, should always be with a mastectomy







