

INTERTROCHANTERIC FRACTURES

Intertrochanteric fractures are, by definition, extracapsular. Trochanteric fractures unite quite easily and seldom cause avascular necrosis. Divided into stable and unstable varieties.

Clinical features

The patient is usually old and is unable to stand. The leg is shorter and more externally rotated than with a Trans cervical fracture (because the fracture is extracapsular) and the patient cannot lift his or her leg.

Treatment

Almost always treated by early internal fixation because

- (a) To obtain the best possible position
- (b) To get the patient up and walking as soon as possible and thereby reduce the complications associated with prolonged sitting.

Complications

EARLY complications are the same as with femoral neck fractures, reflecting the fact that most of these patients are in poor health.

LATE

Failed fixation if union is delayed, the implant itself may break. In either event, reduction and fixation may have to be re-done.

Malunion Varus and external rotation deformities are common. Fortunately they are seldom severe and rarely interfere with function.

Non-union Intertrochanteric fractures seldom fail to unite. If healing is delayed (say beyond 6 months) the fracture probably will not join and further operation is advisable;

SUBTROCHANTERIC FRACTURES

Subtrochanteric fractures have several features which make them interesting (and challenging to treat):

1. Blood loss is greater than with femoral neck or trochanteric fractures – the region is covered with anastomosing branches of the medial and lateral circumflex femoral arteries which come off the profunda femoris trunk.
2. There may be subtle extensions of the fracture into the intertrochanteric region, which may influence the manner in which internal fixation can be performed.
3. The proximal part is abducted and externally rotated by the gluteal muscles, and flexed by the psoas. The shaft of the femur has to be brought into a position to match the proximal part or else a Malunion is created corrected by internal fixation.

Clinical features

The leg lies in neutral or external rotation and looks short; the thigh is markedly swollen. Movement is excruciatingly painful.

X-ray

May be transverse, oblique or spiral, and is frequently comminuted.

Three important features should be looked for, as the presence of any one will influence treatment:

- (1) An unusually long fracture line extending proximally towards the greater trochanter and piriform fossa;
- (2) A large, displaced fragment which includes the lesser trochanter; and
- (3) Lytic lesions in the femur.

Treatment

Traction may help to reduce blood loss and pain. It is an interim measure until the patient, especially if elderly and with multiple medical problems, is stabilized and prepared for surgery. Open reduction and internal fixation is the treatment of choice.

Complications

Malunion Varus and rotational malunions are fairly common. If the degree of malunion produces symptoms, it may need operative correction.

Non-union This occurs in about 5 per cent of cases; it will require operative correction of any deformity, renewed fixation and bone grafting.

FEMORAL SHAFT FRACTURES

Mechanism of injury

This is usually a fracture of young adults and results from a high energy injury. Diaphyseal fractures in elderly patients should be considered 'pathological' until proved otherwise. In children under 4 years the possibility of physical abuse must be kept in mind.

Clinical features

There is swelling and deformity of the limb, and any attempt to move the limb is painful. With the exception of a fracture through pathological bone

Emergency treatment

Traction with a splint(Thomas Splint) is first aid for a patient with a femoral shaft fracture. temporary stabilization helps to control pain, reduces bleeding and makes transfer easier. Shock should be treated; blood volume is restored and maintained ,and a definitive plan of action instituted as soon as the patient's condition has been fully assessed.

THE ISOLATED FEMORAL SHAFT FRACTURE

Traction, bracing and spica casts

traction

The main indications for traction are

- (1) fractures in children;
- (2) contraindications to anaesthesia; and
- (3) lack of suitable skill or facilities for internal fixation.

It is a poor choice for elderly patients, for pathological fractures and for those with multiple injuries.

Plate and screw fixation

The main indications for plates are

- (1) fractures at either end of the femoral shaft, especially those with extensions into the supracondylar or pertrochanteric areas,
- (2) a shaft fracture in a growing child, and
- (3) a fracture with a vascular injury which requires repair

Intramedullary nailing

External fixation

The main indications for external fixation are

- (1) treatment of severe open injuries;
- (2) management of patients with multiple injuries where there is a need to reduce operating time and prevent the 'second hit'; and
- (3) the need to deal with severe bone loss by the technique of bone transport.

External fixation is also useful for

- (4) treating femoral fractures in adolescents

Treatment of open fractures

Open femoral fractures should be carefully assessed for (1) skin loss; (2) wound contamination; (3) muscle ischaemia; and (4) injury to vessels and nerves.

Complications of femoral shaft fractures

EARLY

Shock One or two litres of blood can be lost even with a closed fracture,

Fat embolism Fracture through a large marrow- filled cavity almost inevitably results in small showers of fat emboli being swept to the lungs.

Thromboembolism Prolonged traction in bed predisposes to thrombosis. Movement and exercise are important in preventing this, but high-risk patients should be given prophylactic anticoagulants as well.

Infection

LATE

Delayed union and non-union

Malunion

Joint stiffness

Refracture and implant failure

FEMORAL SHAFT FRACTURES IN CHILDREN

Mechanism

In children under 2 years of age the commonest cause is child abuse; if there are several fractures in different stages of healing, this is very suspicious. *Pathological fractures* are common in generalized disorders such as spina bifida and osteogenesis imperfecta, and with local bone lesions

Treatment

The principles of treatment in children are the same as in adults but it should be emphasized that in young children open treatment is rarely necessary.

Traction and casts Infants need no more than a few days in balanced traction, followed by a spica cast for another 3–4 weeks

Children between 2 and 10 years of age can be treated either with balanced traction for 2–3 weeks followed by a spica cast for another 4 weeks, or by early reduction and a spica cast from the outset. Shortening of 1–2 cm and angulation of up to 20 degrees are acceptable.

Teenagers require somewhat longer (4–6 weeks) in balanced traction the limit of acceptable angulation in this age group is 15 degrees in the anteroposterior x-ray and 25 degrees in the lateral. If a satisfactory reduction cannot be achieved by traction, internal (plates or flexible intramedullary nails) or external fixation is justified. This applies to older children and those with multiple injuries.

Operative treatment This is growing in popularity as there is:

- (1) a shorter in-patient stay (and for the child, a quick return home);
- (2) a lower incidence of malunion.

Surgical options include fixation with flexible intramedullary nails or trochanteric entry-point rigid nails with interlocking screws

Complications

Shortening anything up to 2 cm is quite acceptable in young children, bone to grow faster for up to 2 years after the injury.

Malunion It is probably wise to observe a malunited fracture for 2 years before offering corrective osteotomy.

SUPRACONDYLAR FRACTURES OF THE FEMUR

- (a) in young adults, usually as a result of high energy trauma, and
- (b) in elderly, osteoporotic individuals.

Clinical features

The knee is swollen because of a haemarthrosis – this can be severe enough to cause blistering later. Movement is too painful to be attempted. The tibial pulses should always be checked to ensure the popliteal artery was not injured in the fracture.

X-RAY

factors influence the type of internal fixation

- (a) whether there is a fracture into the joint and if it is comminuted;
- (b) the size of the distal segment
- (c) whether the bone is osteoporotic.

Treatment

Non-operative by traction If the fracture is only slightly displaced and extra-articular, or if it reduces easily with the knee in flexion, for 4–6 weeks

Surgery Operative treatment with internal fixation can enable accurate fracture reduction, especially of the joint surface, and early movement.

Several different devices are available:

1. Locked intramedullary nails
2. *Plates that are applied to the lateral surface of the femur:* traditional angled blade-plates or 95 degree condylar screw-plates.
3. *Simple lag screws*

Complications

EARLY Arterial damage , LATE Joint stiffness, Malunion ,Non-union

FRACTURE-SEPARATION OF DISTAL FEMORAL EPIPHYSIS

Salter-Harris fracture of epiphysis

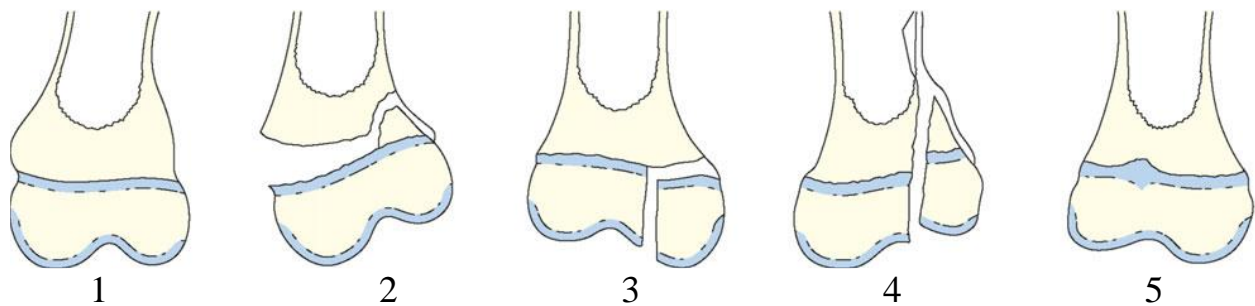
Type 1 – separation of the epiphysis – which usually occurs in infants but is also seen at puberty as a slipped femoral epiphysis.

Type 2 – fracture through the physis and metaphysis – is the commonest; it occurs in older children and seldom results in abnormal growth.

Type 3 – an intra-articular fracture of the epiphysis – needs accurate reduction to restore the joint surface.

Type 4 – splitting of the physis and epiphysis – damages the articular surface and may also cause abnormal growth; if it is displaced it needs open reduction.

Type 5 – crushing of the physis – may look benign but ends in arrested growth.



Clinical features

The knee is swollen and perhaps deformed. The pulses in the foot should be palpated because, with forward displacement of the epiphysis, the popliteal artery may be obstructed by the lower femur.

Treatment

The fracture can usually be perfectly reduced manually, but further x-ray checks will be needed over the next few weeks to ensure that reduction is maintained. Occasionally open reduction is needed; a flap of periosteum may be trapped in the fracture line. Salter-Harris types 3 and 4 should be accurately reduced and fixed.

Complications

EARLY *Vascular injury* .LATE *Physeal arrest*