

FRACTURES AROUND THE ELBOW IN CHILDREN

Though all the epiphyses are in some part cartilaginous, the secondary ossific centres can be seen on xray; they should not be mistaken for fracture fragments! The average ages at which the ossific centres appear are easily remembered by the mnemonic CRITOE

: Capitulum – 2 years. Radial head – 4 years. Internal (medial) epicondyle – 6 years. Trochlea – 8 years. Olecranon – 10 years. External (lateral) epicondyle – 12 years.

SUPRACONDYLAR FRACTURES

The distal fragment may be displaced either posteriorly or anteriorly. Posterior angulation or displacement (95 per cent of all cases)

Classification

Type I is an undisplaced fracture.

Type II is an angulated fracture with the posterior cortex still in continuity.

IIA – a less severe injury with the distal fragment merely angulated.

IIB – a severe injury; the fragment is both angulated and malrotated.

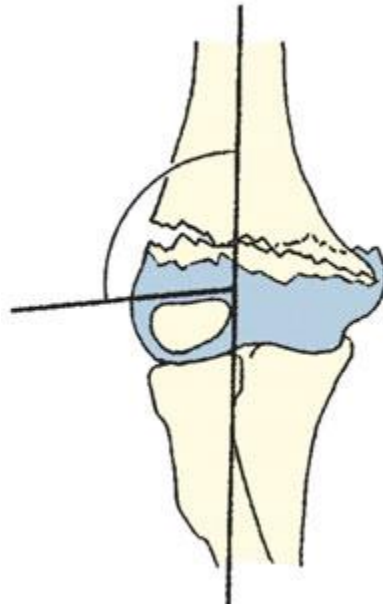
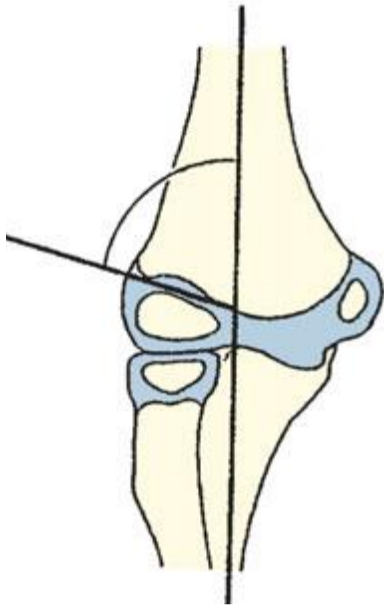
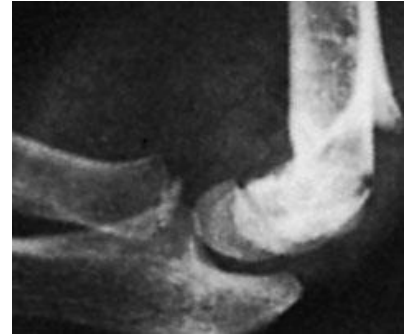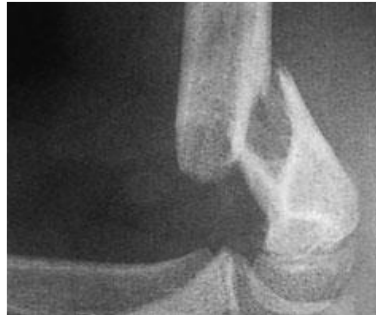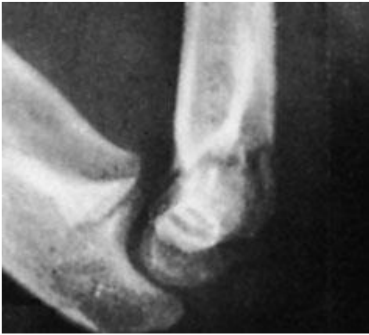Type III is a completely displaced fracture (although the posterior periosteum is usually still preserved, which will assist surgical reduction).

Clinical features

pain and the elbow is swollen; with a posteriorly displaced fracture the S-deformity. It is essential to feel the pulse and check the capillary return. The wrist and the hand should be examined for evidence of nerve injury.

X-ray

The fracture is seen most clearly in the lateral view.



Baumann's angle

This is the angle subtended by the longitudinal axis of the humeral shaft and a line through the coronal axis of the capitellar physis Normally this angle is less than 80 degrees

Treatment

If there is even a suspicion of a fracture, the elbow is gently splinted in 30 degrees of flexion to prevent movement and possible neurovascular injury during the x-ray examination.

UNDISPLACED FRACTURE

immobilized at 90 degrees splint or cast and the arm is supported by a sling. It is essential to obtain an x-ray 5–7 days later The splint is retained for 3 weeks and supervised movement is then allowed.

ANGULATED FRACTURE or DISPLACED

fixed with percutaneous crossed K-wires and removed after 3 week after which movements are begun.

OPEN REDUCTION

This is sometimes necessary for (1) a fracture which simply cannot be reduced closed; (2) an open fracture; or (3) a fracture associated with vascular damage.

Complications

EARLY

Vascular injury or Nerve injury

LATE

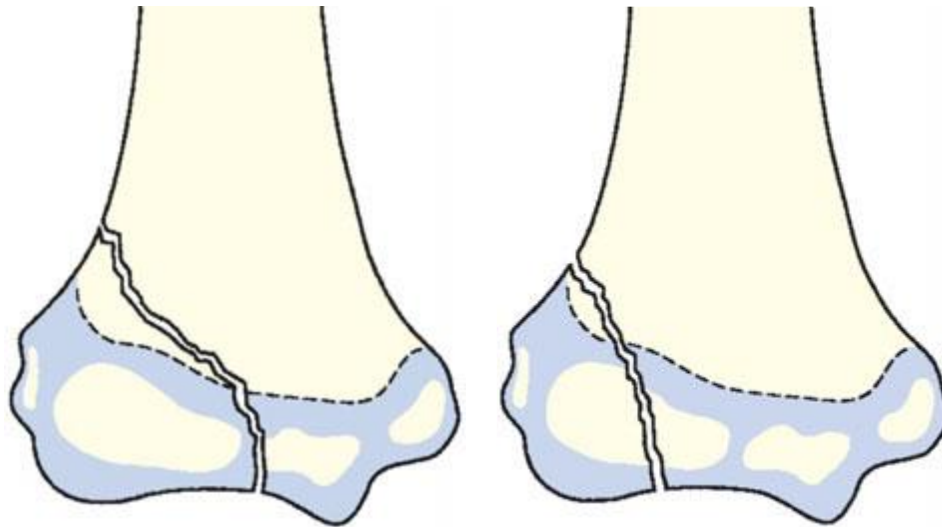
Malunion, Elbow stiffness and myositis ossificans.

FRACTURES OF THE LATERAL CONDYLE

capitellar epiphysis begins to ossify during the first year of life and fuses with the shaft at 12–16 years. Between these ages it may be sheared off or avulsed by forceful traction.

Clinical features

The elbow is swollen and deformed. There is tenderness over the lateral condyle. Passive flexion of the wrist (pulling on the extensors) may be painful.



Treatment

If there is no displacement the arm can be splinted in a backslab with the elbow flexed 90 degrees. repeat the x-ray after 5 days to make sure that the fracture has not displaced.

The splint is removed after 2 weeks and exercises are encouraged.

A displaced fracture requires accurate reduction and internal fixation with percutaneous pins

. The arm is immobilized in a cast; cast and pins are removed after 3 or 4 weeks.

Complications

Non-union and malunion

Recurrent dislocation

SEPARATION OF THE MEDIAL EPICONDYLE

The medial epicondyle begins to ossify at the age of about 5 years and fuses to the shaft at about 16; between these ages it may be avulsed by a severe muscle or ligament strain.

Clinical features

The diagnosis should be suspected if injury is followed by pain, swelling and bruising on the medial side of the elbow. If the joint is dislocated, deformity is of course obvious. Sensation and power in the fingers should be tested to exclude concomitant ulnar nerve damage.

Treatment

Minor displacement may be disregarded. This is an extra-articular fracture, so the elbow can be mobilized as soon as the child wishes. If the epicondyle is trapped in the joint it must be freed. Manipulation with the elbow in valgus and the wrist hyperextended (to pull on the flexor muscles) may be successful; if this fails, the joint must be opened (the ulnar nerve must be visualized and protected) and the fragment retrieved and fixed back in position.

Displaced fractures which are not trapped in the joint usually do not need to be operated upon: however, if there is valgus instability (because the medial collateral ligament complex is attached to the fragment) then reduction and pinning is recommended.

Complications

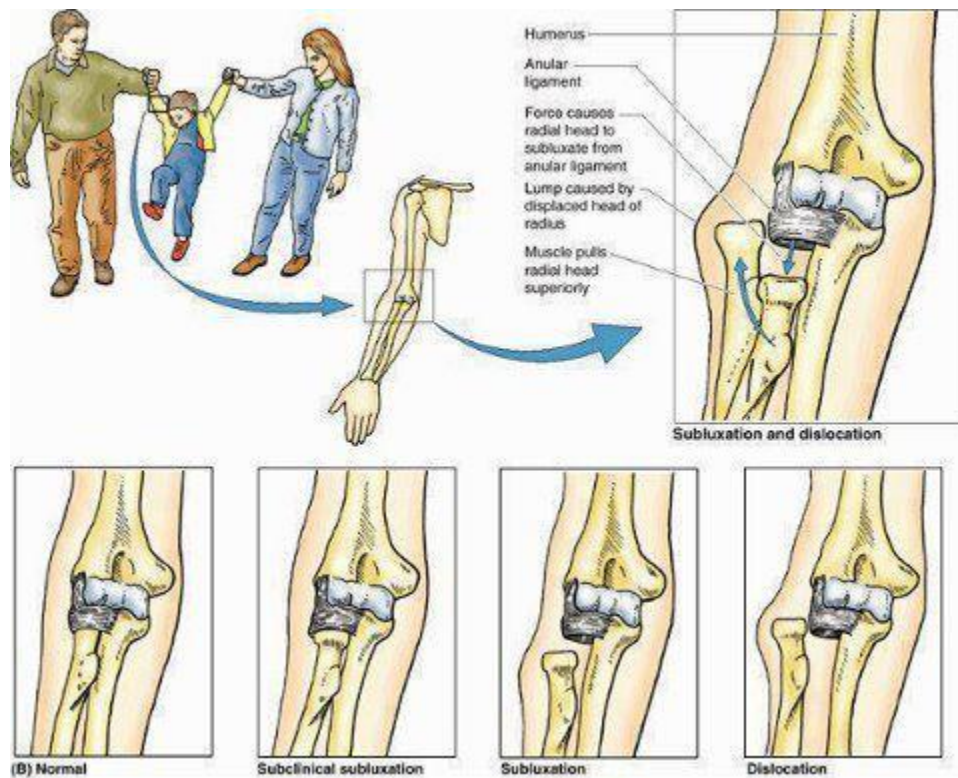
EARLY Ulnar nerve damage is not uncommon.

LATE

Stiffness of the elbow is common

SUBLUXATION OF THE RADIAL HEAD (‘PULLED ELBOW’)

In young children the elbow may be injured by pulling on the arm, usually with the forearm pronated. It is sometimes called subluxation of the radial head; more accurately, it is a subluxation of the orbicular ligament which slips up over the head of the radius into the radiocapitellar joint. A child aged 2 or 3 years is brought with a painful, dangling arm: there is usually a history of the child being jerked by the arm and crying out in pain. The forearm is held in pronation and extension, and any attempt to supinate it is resisted. There are no x-ray changes. A dramatic cure is achieved by forcefully supinating and then flexing the elbow; the ligament slips back with a snap.



FRACTURES OF THE RADIUS AND ULNA

Fractures of the shafts of both are quite commonly. A twisting force leads to a spiral fracture with the bones broken at different levels. An angulating force causes a transverse fracture of both bones at the same level. A direct blow causes a transverse fracture of just one bone, usually the ulna. Bleeding and swelling of the muscle compartments of the forearm may cause circulatory impairment.

Clinical features X-RAY

Treatment

CHILDREN

closed treatment is usually successful. The fragments are held in a well-moulded full-length cast, from axilla to metacarpal shafts (to control rotation). The cast is applied with the elbow at 90 degrees. The position is checked by x-ray splintage is retained (usually 6–8 weeks).

Occasionally an **operation** is required, either if the fracture cannot be reduced or if the fragments are unstable. Fixation with intramedullary rods is preferred, but they should be inserted with great care to avoid injury to the growth plates.

Alternatively, a plate or K-wire fixation can be used. Childhood fractures usually remodel well, but not if there is any rotational deformity or an angular deformity of more than 15 degrees in children under 6 years or 10 degrees in children between 6 and 12. In those over 12 years old even slight angular deformities are unlikely to remodel satisfactorily.

ADULTS

Unless the fragments are in close apposition, reduction is difficult and re-displacement in the cast almost invariable. So predictable is this outcome that most surgeons opt for open reduction and internal fixation from the outset. After the operation the arm is kept elevated until the swelling subsides.

Complications

EARLY

Nerve injury ,proximal third of the radius risks damage to the posterior interosseous nerve

Vascular injury Injury to the radial or ulnar artery seldom presents any problem, as the collateral circulation is excellent.

Compartment syndrome the diagnosis more difficult, if the forearm is wrapped up in plaster.

LATE

Delayed union and non-union Most fractures of the radius and ulna heal within 8–12 weeks

Malunion

Complications of plate removal Removal of plates and screws is often regarded as a fairly innocuous procedure. Beware! Complications are common and they include damage to vessels and nerves, infection and fracture through a screw-hole.

