

Disorders of the Lower Lacrimal System

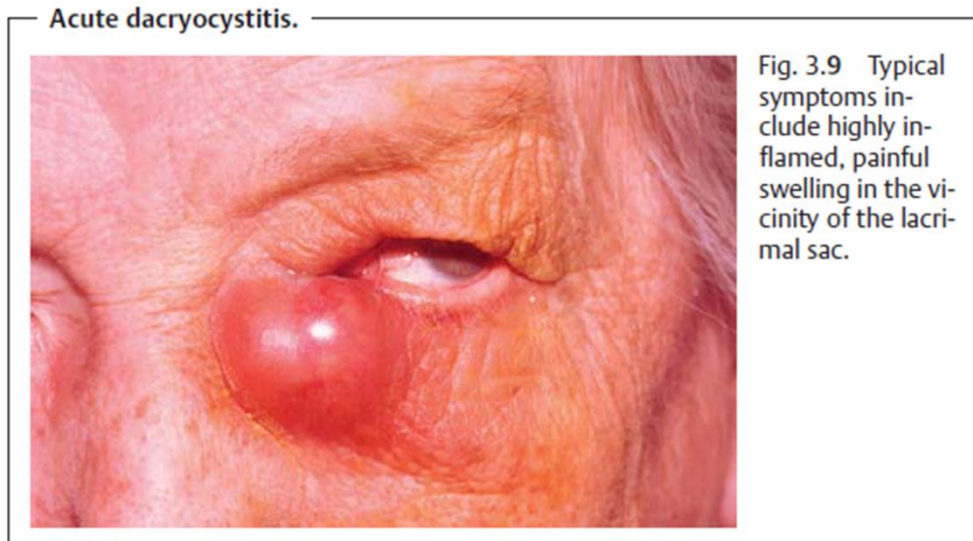
1. Acute Dacryocystitis
2. Chronic Dacryocystitis
3. Neonatal Dacryocystitis
4. Canaliculitis

Dacryocystitis

- A. Inflammation of the lacrimal sac
- B. Is the *most frequent* disorder of the lower lacrimal system
- C. It is usually the result of obstruction of the nasolacrimal duct
- D. Is *unilateral in most cases*.

Acute Dacryocystitis

- **Epidemiology:** The disorder most frequently affects adults between the ages of 50 and 60.
- **Etiology:** The cause is usually a ***stenosis within the lacrimal sac***. The retention of tear fluid leads to infection from staphylococci, pneumococci, *Pseudomonas*, or other pathogens.
- **Symptoms:**
 - A. Highly inflamed, painful swelling in the vicinity of the lacrimal sac
 - B. Malaise, fever,
 - C. Involvement of the regional lymph nodes.
 - D. The pain may be referred as far as the forehead and teeth.
 - E. An abscess in the lacrimal sac may form in advanced disorders; it can spontaneously rupture the skin and form a draining fistula.



Note

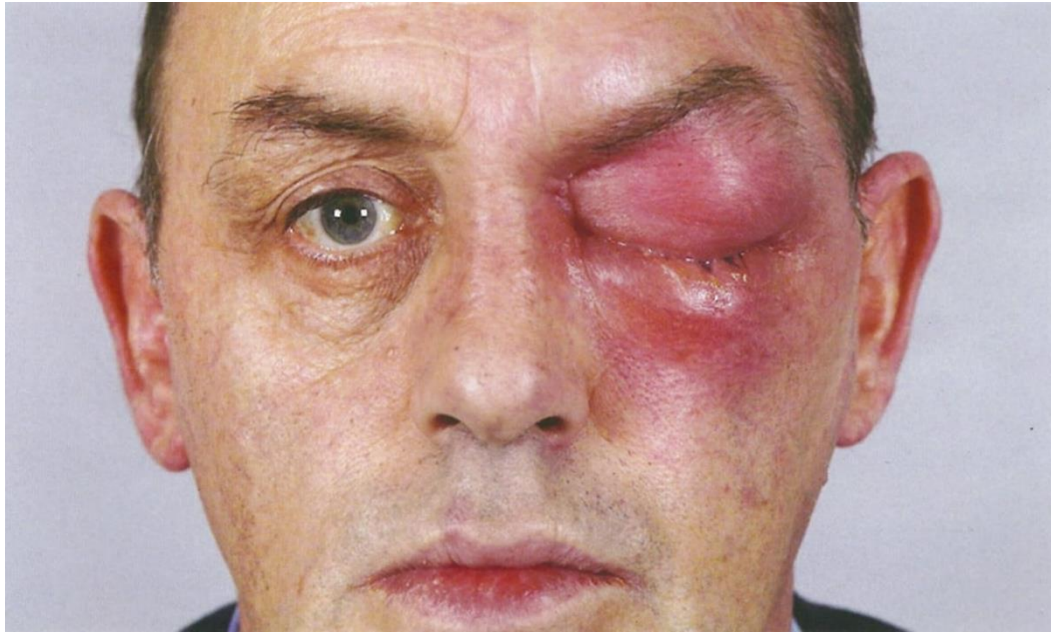Acute inflammation that has spread to the surrounding tissue of the eyelids and cheek entails a risk of sepsis and cavernous sinus thrombosis, which is a life-threatening complication.

Diagnostic considerations:

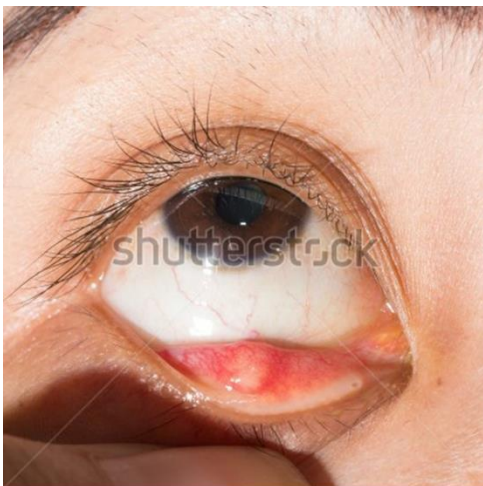- Radiographic contrast studies or digital subtraction **dacryocystography** can visualize the obstruction for preoperative planning.
- These studies should be avoided during the acute phase of the disorder because of the risk of pathogen dissemination.

Differential diagnosis:

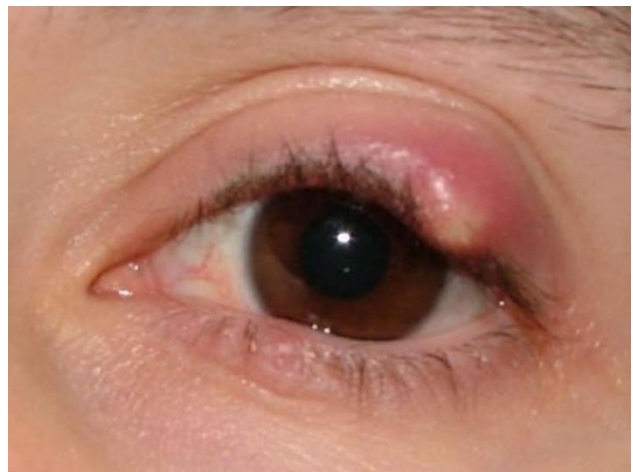
- A. Hordeolum** (small, circumscribed, non-mobile inflamed swelling).
- B. Orbital cellulitis** (usually associated with reduced motility of the eyeball).



Orbital cellulitis



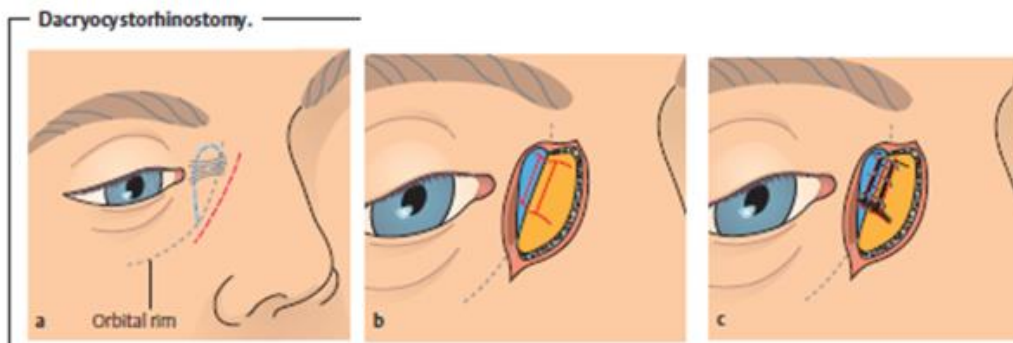
Internal hordeolum



External hordeolum

Treatment:

- **Acute cases** are treated with *local and systemic antibiotics* according to the specific pathogens detected. *Disinfectant compresses* (such as a 1:1000 Rivanol solution) can also positively influence the clinical course of the disorder.
- **Pus** from a *fluctuating abscess* is best drained through a *stab incision* following cryoanesthesia with a refrigerant spray.
- Treatment after **acute symptoms have subsided** often requires surgery (dacryocystorhinostomy; Figs. 3.10a–c) to achieve persistent relief.
- Also known as a lower system bypass, this operation involves opening the lateral wall of the nose and bypassing the nasolacrimal duct to create a direct connection between the lacrimal sac and the nasal mucosa.



A skin incision is made, and the orbital rim is exposed. Then a window is opened to expose the nasal mucosa. The nasal mucosa and the lacrimal sac are both incised in an H-shape and door-like flaps are raised. The anterior and posterior mucosal flaps are then sutured together. This creates a new drainage route for the tear fluid that bypasses the nasolacrimal duct.

Chronic Dacryocystitis

Etiology: Obstruction of the nasolacrimal duct is often secondary to chronic inflammation of the connective tissue or nasal mucosa.

Symptoms and diagnostic considerations:

- A. The *initial characteristic* of chronic dacryocystitis is *increased lacrimation*.
- B. Signs of inflammation are not usually present.
- C. Applying pressure to the inflamed lacrimal sac causes *large quantities of transparent mucoïd pus* to regurgitate through the punctum.

- D. Chronic inflammation of the lacrimal sac can lead to a serpiginous corneal ulcer.
- **Treatment:** Surgical intervention is the only effective treatment in the vast majority of cases. This involves either a dacryocystorhinostomy (creation of or removal of the lacrimal sac).

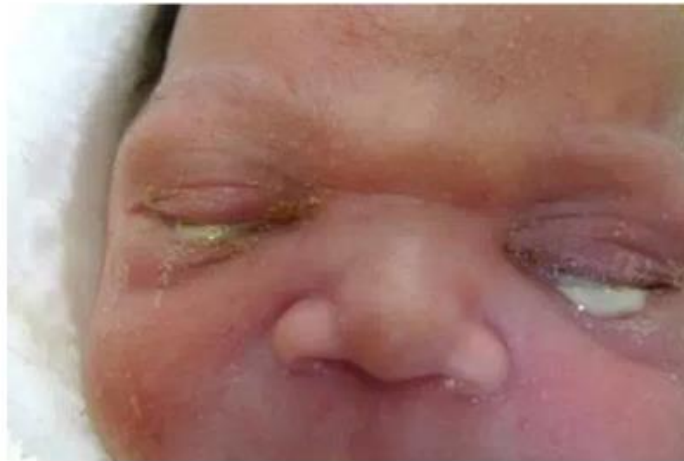Neonatal Dacryocystitis

Etiology: Approximately **6%** of newborns have a stenosis of the mouth of the nasolacrimal duct due to a ***persistent mucosal fold*** (lacrimal fold or valve of Hasner). The resulting retention of tear fluid provides ideal growth conditions for bacteria, particularly staphylococci, streptococci, and pneumococci.

Symptoms and diagnostic considerations: Shortly after birth (usually within two to four weeks), *pus is secreted from the puncta*. The disease continues subcutaneously and pus collects in the palpebral fissure. The *conjunctiva* is *not usually involved*.

Differential diagnosis:

1. Gonococcal conjunctivitis
2. Inclusion conjunctivitis.
3. Silver catarrh (harmless conjunctivitis with slimy mucosal secretion following Credé's method of prophylaxis with silver nitrate).



Gonococcal conjunctivitis

Treatment:

During the first few weeks, the infant should be monitored for *spontaneous opening of the stenosis*. During this period, *antibiotic and anti-inflammatory eye drops and nose drops* (such as erythromycin and xylometazoline 0.5% for infants) are administered.

- **If symptoms persist**, *irrigation* or *probing* under short-acting general anesthesia may be indicated (see Figs. 3.7a–c). Often massaging the region several times daily while carefully applying pressure to the lacrimal sac will be sufficient to open the valve of Hasner and eliminate the obstruction.

Canaliculitis

Definition

- This usually involves *inflammation of the canaliculus*.

Epidemiology and etiology: *Genuine canaliculitis is rare*. Usually a stricture will be present and the actual *inflammation proceeds from the conjunctiva*.

- Actinomycetes (fungoid bacteria) often cause persistent purulent granular concretions that are difficult to express.

Symptoms and diagnostic considerations: The canaliculus region is swollen, reddened, and often tender to palpation. Pus or granular concretions can be expressed.

Treatment: The disorder is treated with antibiotic eyedrops and ointments according to the specific pathogens detected in cytologic smears. Successful treatment occasionally requires surgical incision of the canaliculus.

Muqdad fuad