

Renal Injury

- About 10% of all injuries in the emergency room include the Genito- urinary system.
- Renal injuries are the most common type of urinary system injury.
- In 80% of high-grade renal injury there is associated abdominal visceral injury.

Mechanism

- The kidneys are retroperitoneal structures surrounded by perirenal fat, vertebral column and spinal muscles, the lower ribs, and abdominal contents. They are, therefore, relatively protected from injury, and a considerable degree of force is usually required to injure them (only 1.5–3% of trauma patients have renal injuries).

1. Blunt trauma

- a. Direct blow to the kidney.
- b. Rapid acceleration or rapid deceleration (RTA)
- c. Fall from Height
 - A diseased kidney (hydronephrosis, tumor or cyst) is more readily injured with minimal trauma.
 - Usually the injury is extraperitoneal, (in children) there is peritoneal injury & escape of urine in to the peritoneal cavity.

2. Penetrating injuries to the flank, lower chest, and anterior abdominal

- a. Sharp object, stab
- b. Blast shrapnel's
- c. Bullet & blast injuries
 - Almost always other organ affection
 - Almost always needs surgical exploration
 - Absence of hematuria does not rule out renal injury
 - Vascular injury should not be missed

3. Surgical and Endoscopic causes: PCNL

Clinical features:

1. **Pain:** Local pain, tenderness
2. **Hematuria:**
 - Most important symptom of renal injury. microscopic or gross, early or late.
 - The degree of hematuria does not reflect the severity of renal injury.
 - Absence of hematuria does not exclude renal injury
 - In severe hematuria clot retention may occur.

3. **Abdominal distension** occurs after injury, due to 24 – 48hr retroperitoneal hematoma implicating splanchnic nerves
4. **The hemodynamic status** depends on the extent of the injury & other organ involvement

4. Signs of renal injuries

- Ecchymosis, bruises in the flank, shell inlet and outlet, acute abdomen, palpable loin masses of hematoma or urinoma.

5. Intra-peritoneal leak may cause **ileus**.

6. **Fracture lower ribs and transverse processes** are indirect signs of renal injury.

Investigations

1. **GUE, CBC, Blood Grouping, cross matching, renal function test.**
2. **Imaging Studies**
 - a. **Ultrasonography: retroperitoneal** collection (Hematoma, urinoma).
 - b. **KUB:** Fracture rib or vertebral transverse process
 - c. **Contrast-enhanced CT-scan:**

⇒ The preferred imaging study is If the patient condition is stable.

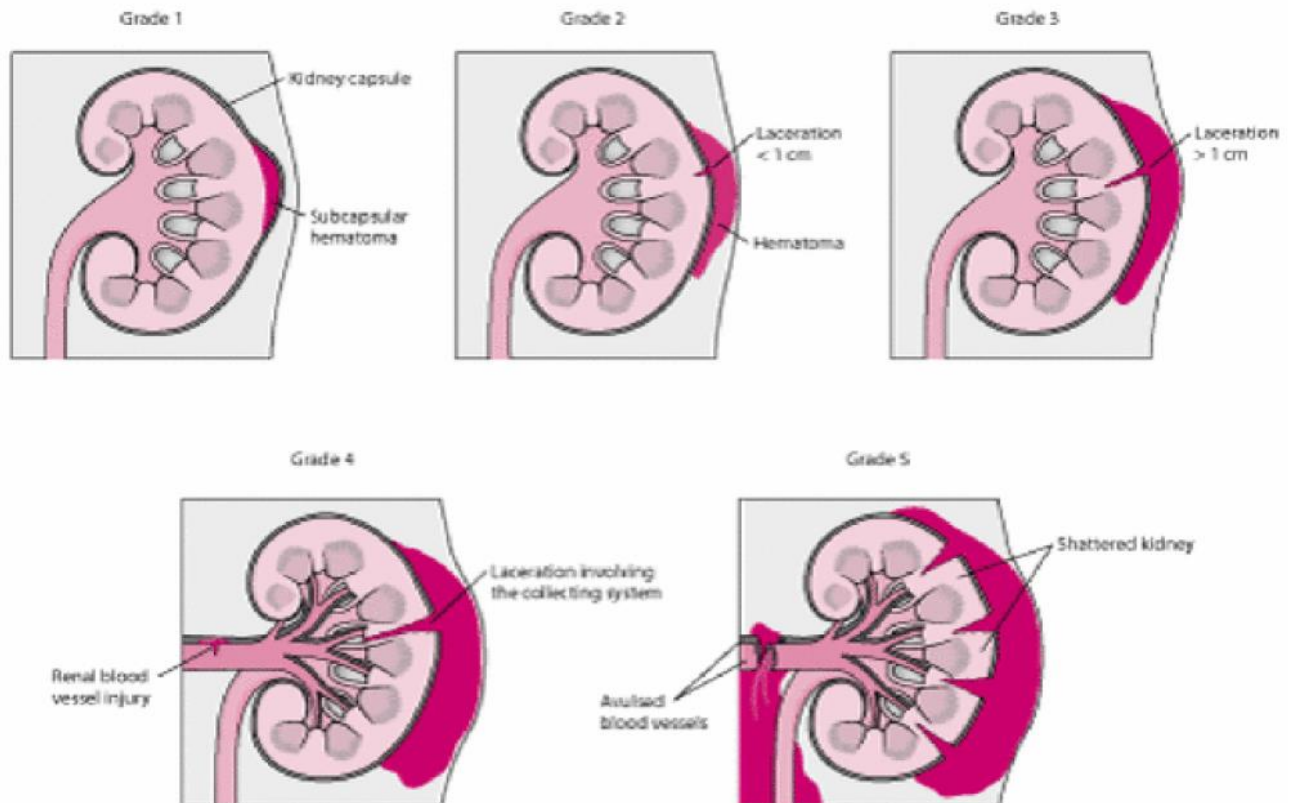
⇒ **Staging:**

1. Extent of renal parenchymal laceration.
2. Urinary extravasation.
3. Extent of retroperitoneal hematoma.

GRADE *	DESCRIPTION OF INJURY
1	Contusion or non-expanding sub-capsular haematoma No laceration
2	Non-expanding peri-renal haematoma Cortical laceration < 1 cm deep (without urinary extravasation)
3	Cortical laceration > 1 cm deep (without urinary extravasation)
4	Laceration : through corticomedullary junction into collecting system Or Vascular : segmental renal artery or vein injury with contained haematoma, or partial vessel laceration, or vessel thrombosis
5	Laceration : shattered kidney Or Vascular : renal pedicle avulsion

Indications for Renal Imaging

- Hematuria is the best indicator of renal injury, and most authors accept as 5 RBC/HPF a significant level.
- 1. All blunt trauma patients with gross hematuria.
- 2. Blunt trauma patients with microscopic hematuria and shock (systolic blood pressure of less than 90 mm Hg any time during evaluation and resuscitation).
- 3. A history of a rapid acceleration or deceleration (e.g. fall from a height, high speed motor vehicle accident) OR Falls from even a low height can cause serious renal injury in the absence of shock.
- 4. Penetrating injuries with any degree of hematuria.



Management

Clinical and radiological assessment: **ABCDE**

- ⇒ A: Airway & cervical spine protection.
- ⇒ B: Breathing.
- ⇒ C: Circulation & control of external bleeding.
- ⇒ D: Disability or neurological status.
- ⇒ E: Exposure (undress) & environment (temperature control)

The hemodynamically stable patient:

- ⇒ History: nature of trauma (blunt, penetrating).
- ⇒ Examination: pulse rate, systolic BP, respiratory rate, location of entry and exit wounds, flank bruising, rib fractures. The lowest recorded systolic BP is used to determine need for renal imaging.

The hemodynamically unstable patient

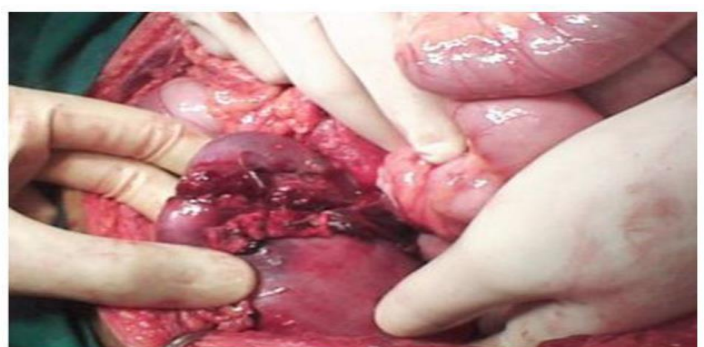
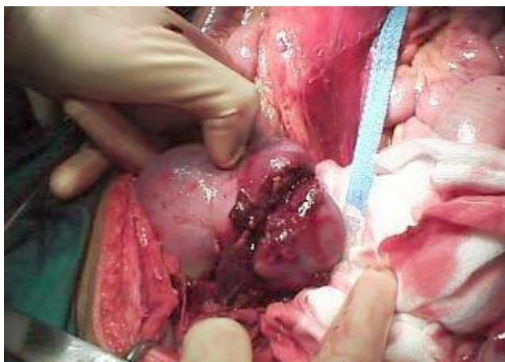- ⇒ Hemodynamic instability may preclude standard imaging such as CT, the patient having to be taken to the operating theatre immediately to control the bleeding. In this situation, an on-table IVU is indicated if:
- ⇒ A retroperitoneal hematoma is found, A renal injury is found which is likely to require nephrectomy.

Conservative care

- Most blunt (95%) and many penetrating renal injuries (50% of stab injuries and 25% of gunshot wounds) can be managed non-operatively.
- 1. Hospital admission & complete Bed rest: Once the gross hematuria clears ambulation is allowed, should gross hematuria recur, bed rest is reinstated. Ambulation without any sequel allows hospital discharge with close clinical follow-up.
- 2. Correct & maintain the hemodynamic status.
- 3. Repeated clinical assessment (Continuous vital signs check), Watch the urine for the depth of hematuria
- 4. Analgesia
- 5. IV fluid hydration & blood replacement (Blood group & cross matching).
- 6. Antibiotics to prevent secondary infection of the hematoma or urinoma.

Surgical exploration

- ⇒ 0-15% of renal injuries need surgical intervention.
- ⇒ High-grade (IV and V) injuries: can be managed non-operatively if they are cardiovascularly stable. However, grade IV and, especially, grade V injuries often require nephrectomy to control bleeding (grade V injuries function poorly if repaired).
- ⇒ The possibility of damage to other abdominal organs is checked during a transperitoneal approach.
- ⇒ Release of the tamponing effect of the perirenal hematoma can result in massive hemorrhage and the surgeon must be fully prepared for this.
- ⇒ When the kidney is irretrievably ruptured or avulsed from its pedicle, nephrectomy is the only course.
- ⇒ A radiologist may be able to stop the hemorrhage by embolization if a bleeding vessel can be identified.



Indications for Exploration

Absolute indications

1. progressive blood loss
2. expanding perinephric hematoma
3. pulsatile perirenal hematoma
4. perirenal infection
5. Hemodynamically is not recoverable
6. The renal vessels are injured
7. another organ involvement cannot be excluded.

Relative indications

1. urinary extravasation
2. nonviable tissue
3. delayed diagnosis of arterial injury
4. segmental arterial injury
5. Incomplete staging.

Complications

Early complications:

1. Bleeding. Hematuria or retroperitoneal bleeding. (resolve in >85%).
2. Urine extravasation resulting in urinoma.
3. Infection (Urinoma or infected hematoma) resulting in perinephric abscess formation.
4. Acute renal failure.
5. Clot retention.

Late complications

1. Hypertension after 3 months, due to renal scarring.
2. Hydronephrosis.
3. Arteriovenous fistula
4. Delayed renal bleeding can occur several weeks after injury, but it usually occurs within 21 days
5. Aneurysm of the renal artery
6. Calculus formation.
7. repeated UTI.

URETERAL INJURIES

⇒ Rare

Etiology

1. External Trauma

- Ureteric injuries after external violence are rare, occurring in less than 4% of cases of penetrating trauma (Gun shot, bullet and shells) and less than 1% of cases of blunt trauma
- Those patients often have significant associated other organs injuries and a devastating degree of mortality that approaches one third.

2. **Surgical Injury:** Difficult pelvic surgery, gynecological, (hysterectomy & CS), or vascular surgery.

3. **Endoscopic:** ureteroscope, TUR & Dormie basket stone extraction
(most common cause).

4. **Hyperextension injury of the spine**

Types: perforation, division or ligation

Bladder injury

- ❖ Bladder injury is often associated with blunt trauma and particularly with pelvic fracture. Some series report up to 90% of bladder ruptures occurring with associated pelvic fracture.
- ❖ Severe associated injuries are often seen when both pelvic fracture and bladder rupture are present, and mortality may occur in 12–22% of cases.

Causes

1. Blunt:

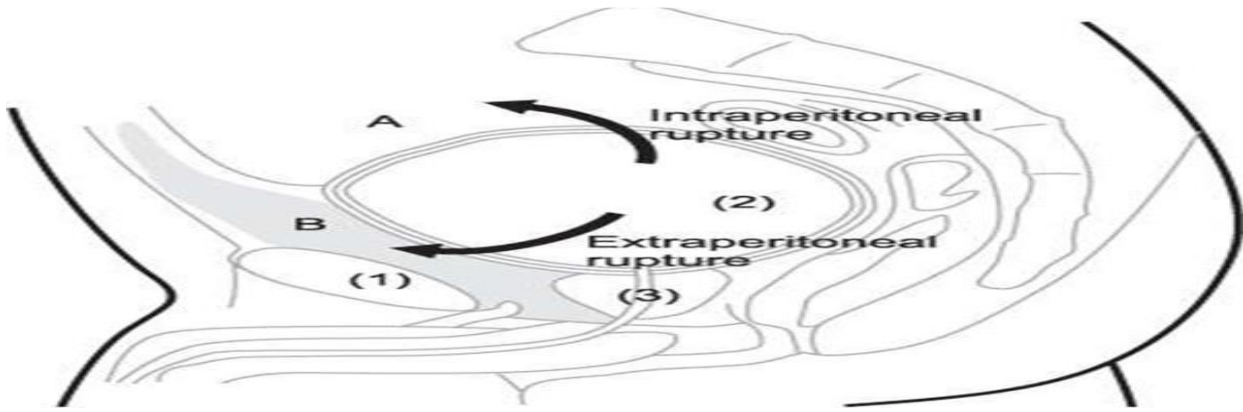
- Motor vehicle accident: 70-97% have associated pelvic fracture
- 10-15% of all pelvic fractures have bladder injury with or without urethral injury.

2. **Penetrating injury:** bullet, knife, foreign body.

3. **Iatrogenic during surgery:** obstetric, gynecologic, general and urology surgery.

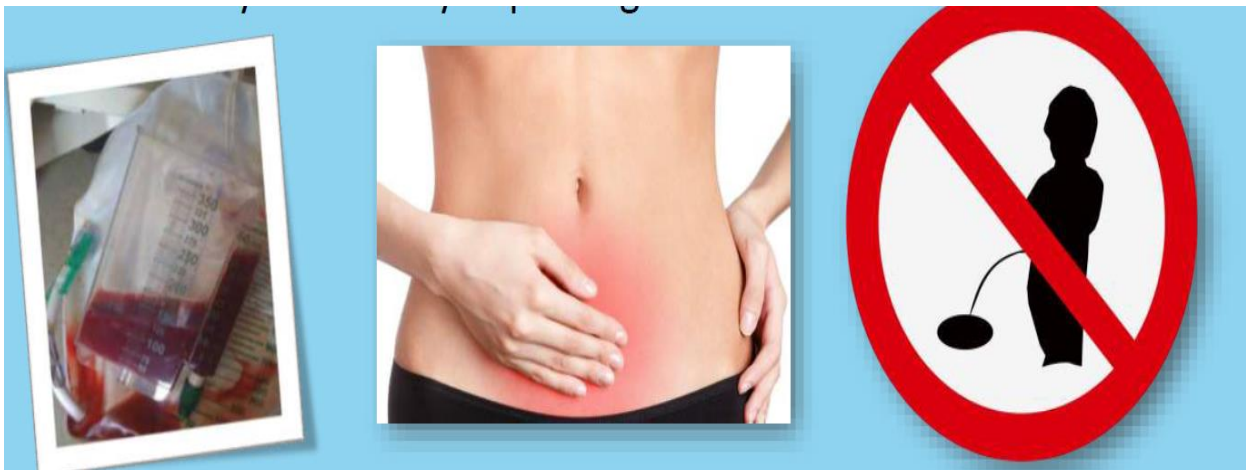Types of bladder injury

1. **Contusion:** Trauma with hematuria with no evidence of bladder leak (no extravasation of urine)
2. **Extraperitoneal rupture (65%):** the peritoneum is intact and urine escapes into the space around the bladder, but not into the peritoneal cavity.
3. **Intraperitoneal rupture (25%):** the peritoneum overlying the bladder is breached allowing urine to escape into the peritoneal cavity.
4. **Combined:** intra and extraperitoneal (10%)



Clinical features

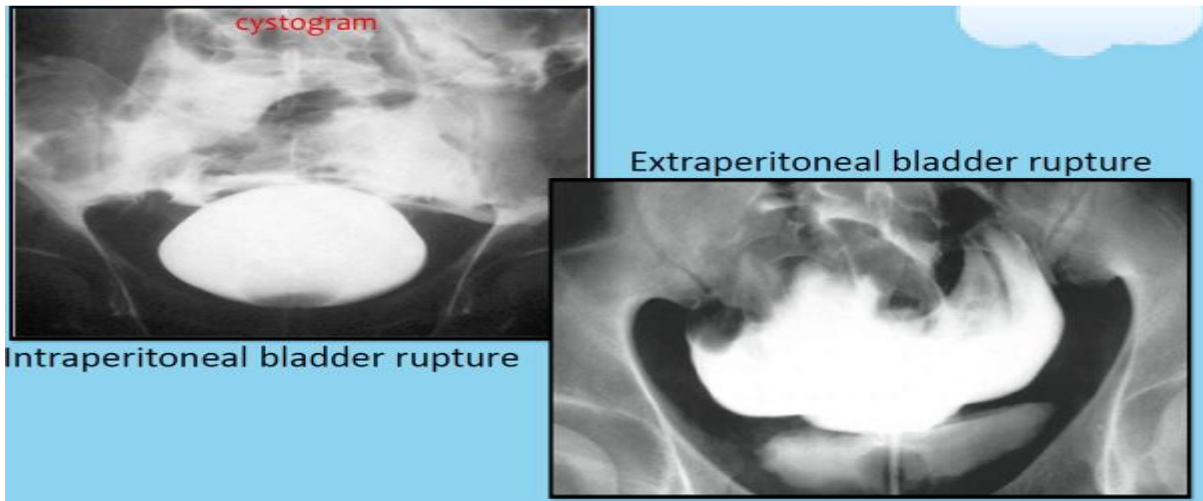
- The classic triad of symptoms and signs suggesting a bladder rupture are:
 1. Gross hematuria.
 2. Suprapubic pain and tenderness with sometimes bruising.
 3. Difficulty or inability in passing urine.
- **Additional signs are as follows:**
 4. Abdominal distension
 5. Absent bowel sounds (indicating an ileus from urine in the peritoneal cavity)
 6. Fever in peritonitis
 7. Urine ascites
 8. Increased BUN/Cr
 9. Free fluid on abdominal CT or ultrasound
 10. Enlarged scrotum



Diagnosis

1. Retrograde cystography

- Foley's catheter is inserted and 350ml of diluted contrast in an adult and $\{(age + 2) \times 30\}$ mL in children is injected to the bladder then x-ray image is taken.
- In extraperitoneal perforations, extravasation of contrast is limited to immediate area surrounding the bladder (a dense "flame-shaped" collection of contrast).
- In intraperitoneal perforations, loops of bowel or the lower lateral portion of the peritoneal cavity may be outlined by the contrast.

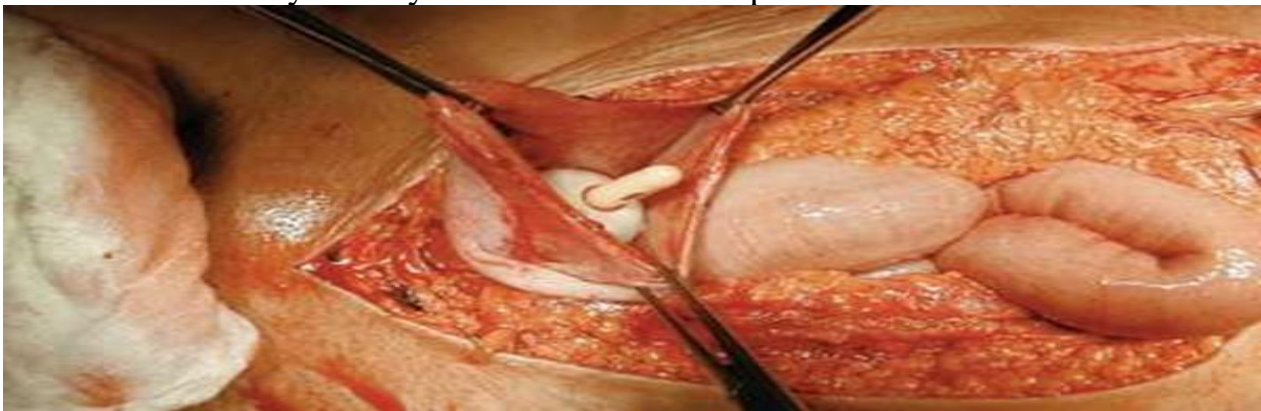

2. CT cystography:

- A “full-bladder” phase is required. CT cystography is usually more appropriate, since many trauma patients are already undergoing CT for other abdominal, chest, head, or pelvic injuries.

Methods to diagnose bladder rupture intraoperatively:

1. Direct inspection of the bladder
2. Fill the bladder with Normal saline or colored dye (e.g. indigo carmine or methylene blue).
3. Cystoscopy
4. Intentional cystotomy for direct internal inspection of the bladder.



Management

1. Bladder contusion

- a. Adequate drainage of the bladder should result in resolution within a few days.
- b. Follow-up cystography is recommended to assess integrity of the bladder wall.

2. Intraperitoneal rupture

- a. Usually requires exploratory laparotomy, cystotomy and suturing of the bladder wall defect, urethral catheter placement, and water-tight bladder closure in 2 or 3 layers with absorbable suture.
- b. suprapubic tube may be considered for a complex bladder repair, significant ongoing gross hematuria, or patients that will require long term catheterization.
- c. Antibiotics

3. **Extraperitoneal rupture**

A. **Extraperitoneal** When conditions are ideal.

1. use bladder drainage with a urethral catheter for about 2 weeks followed by a cystogram to confirm the perforation has healed. If extravasation is noted, replace the catheter for 2 more weeks and repeat imaging; some injuries may take up to 6 weeks to heal. If no urinary extravasation exists, the catheter can be removed.
2. Antibiotics on day of injury until 3d after Foley removed.

B. **Open surgical repair** (as described for intraperitoneal bladder rupture) is recommended for any of the following scenarios.

1. If the bladder was opened to place a suprapubic catheter for a urethral injury or Bone spike protruding into the bladder on CT.
2. Injuries to the bladder discovered intraoperatively during nonurological surgery
3. Injuries occurring as a result of penetrating trauma
4. Poor urinary drainage due to clot obstruction.
5. Associated rectal or vaginal perforation.

Complications

1. Complications of bladder injury are primarily due to a delay in diagnosis leading to azotemia, ascites, and sepsis.
2. Vesical fistula when other organ injuries are present (Vesicovaginal fistula, ureterovesical fistula, rectovesical fistulae).
3. Bladder neck injury, if not identified and repaired, may result in incontinence.
4. Persistent extravasation suggests catheter obstruction, bony fragments, or ischemic complications of injury.

Thank You

2021-2022