Pathology lecture

Dr.Aseel Hashim

Sunday 6/10/2013

- Degeneration
- Pigmentation
- Cellular adaptation
- Calcifications
- Amyloidosis



Degeneration:

Definition:- Visible changes which is short of necrosis, its form of cells injury and damage which is characterized by:

1. **Disturbances of intracellular metabolism.**
2. **Swelling of the cells.**
3. **Accumulations in the cytoplasm of substances that are usually not visible or absent or present only in small amount in the cytoplasm.**

So protein, carbohydrates and lipid can accumulated in cells and sometime cause cellular injury, they may be (i.e. intracellular accumulation)

1. A normal cellular constituent accumulating in excess.

2. An abnormal substances, usually a product of abnormal metabolism.

3. A pigments



Fatty changes:

This refers to abnormal accumulation of fat of triglyceride type within parenchymal cells, it's an example of reversible (non-lethal) cell injury and it's often seen in the liver because of central of this organ in fat metabolism.

Free fatty acids are transported to the liver from two sources:

1. Adipose tissue.
2. Ingested food.



In the liver these fatty acids are esterified to triglyceride. Release of triglyceride from the liver requires their association with carrier proteins (apoproteins) such complexes circulated in the blood as lipoproteins.

Excessive accumulation of triglyceride within the liver (fatty changes) may result from defect in any on of the above steps from entry till their exit from the hepatocytes which include



1. Excessive entry of free fatty acids into the liver (e.g. starvation, corticosteroid therapy).
2. Enhanced fatty acid synthesis.
3. Decreased fatty acid oxidations.
4. Decreased apoproteins synthesis e.g. malnutrition.
5. Impaired lipoprotein secretion from the liver e.g. alcohol.



Gross features of fatty changes:

In the liver, mild fatty changes show no gross changes but with progressive accumulation, the organ enlarges, yellow, soft and greasy to touch.

Microscopical features of fatty changes:

_In early stages, there are small fat vacuoles around the nucleus.

_With progression, the vacuoles fuse together creating clear, large space that displaced the nucleus to the periphery.

FATTY LIVER



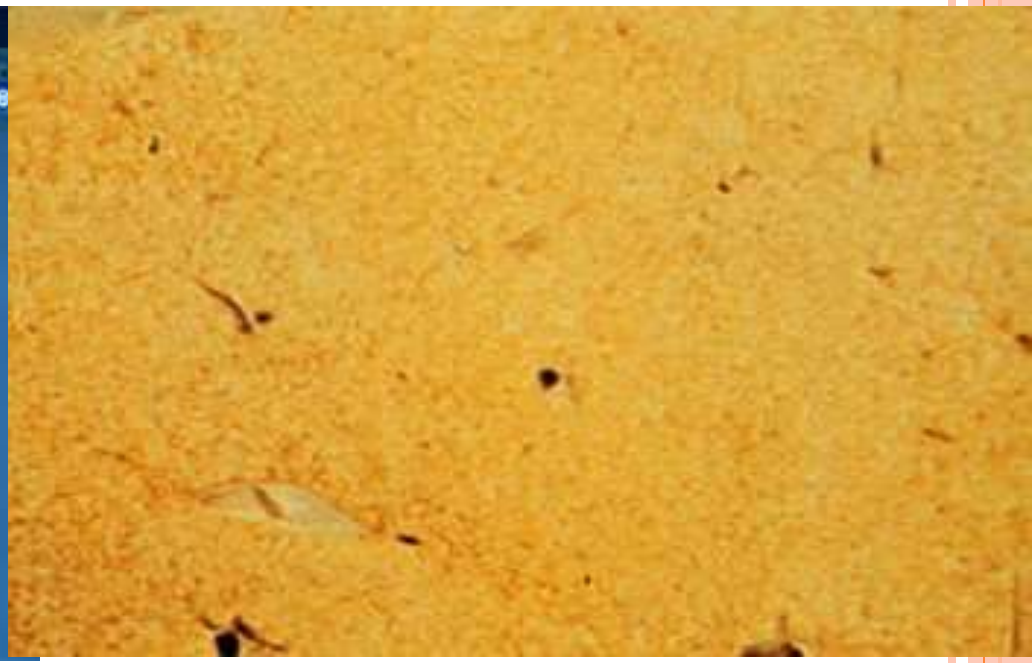

FATTY LIVER

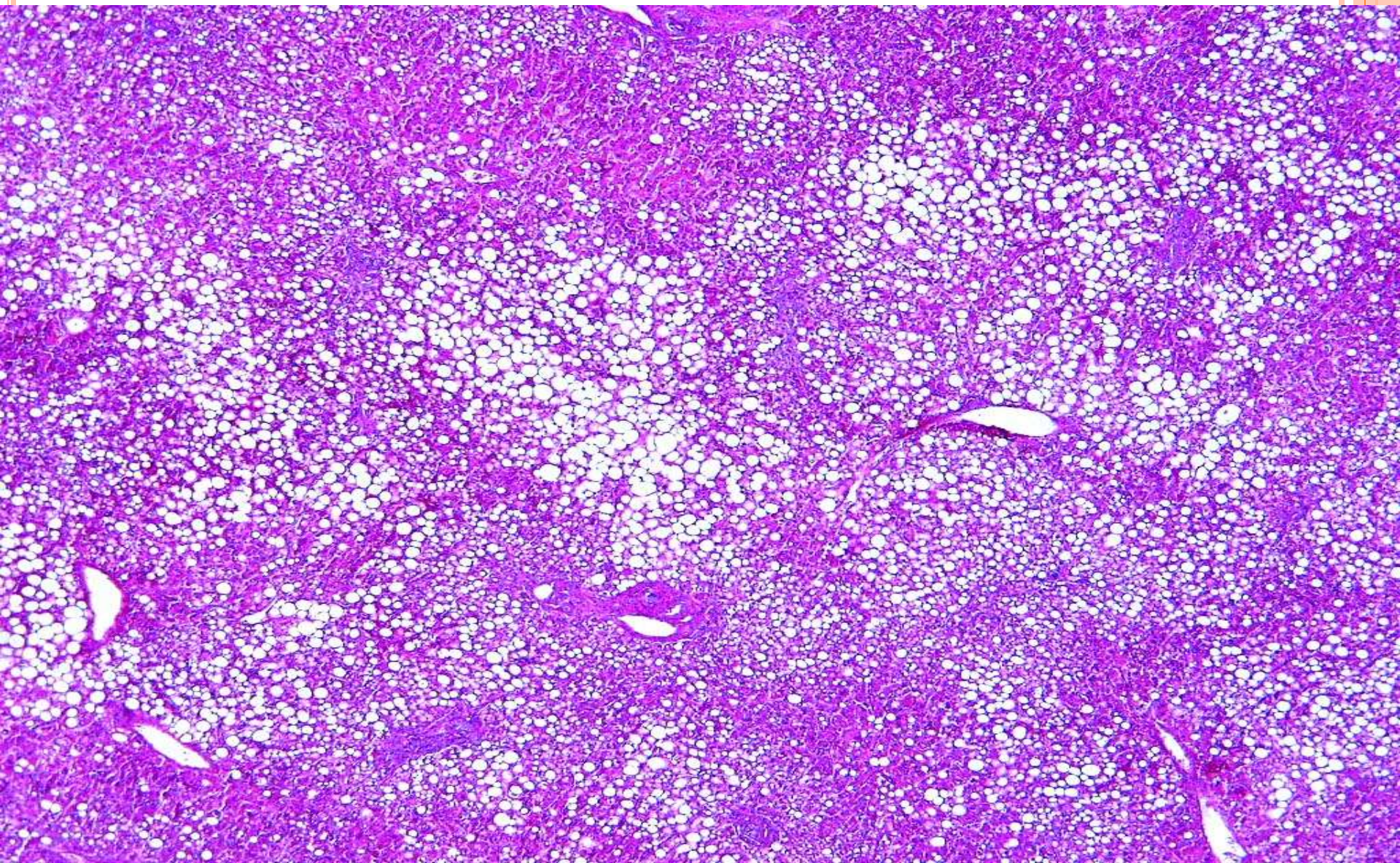

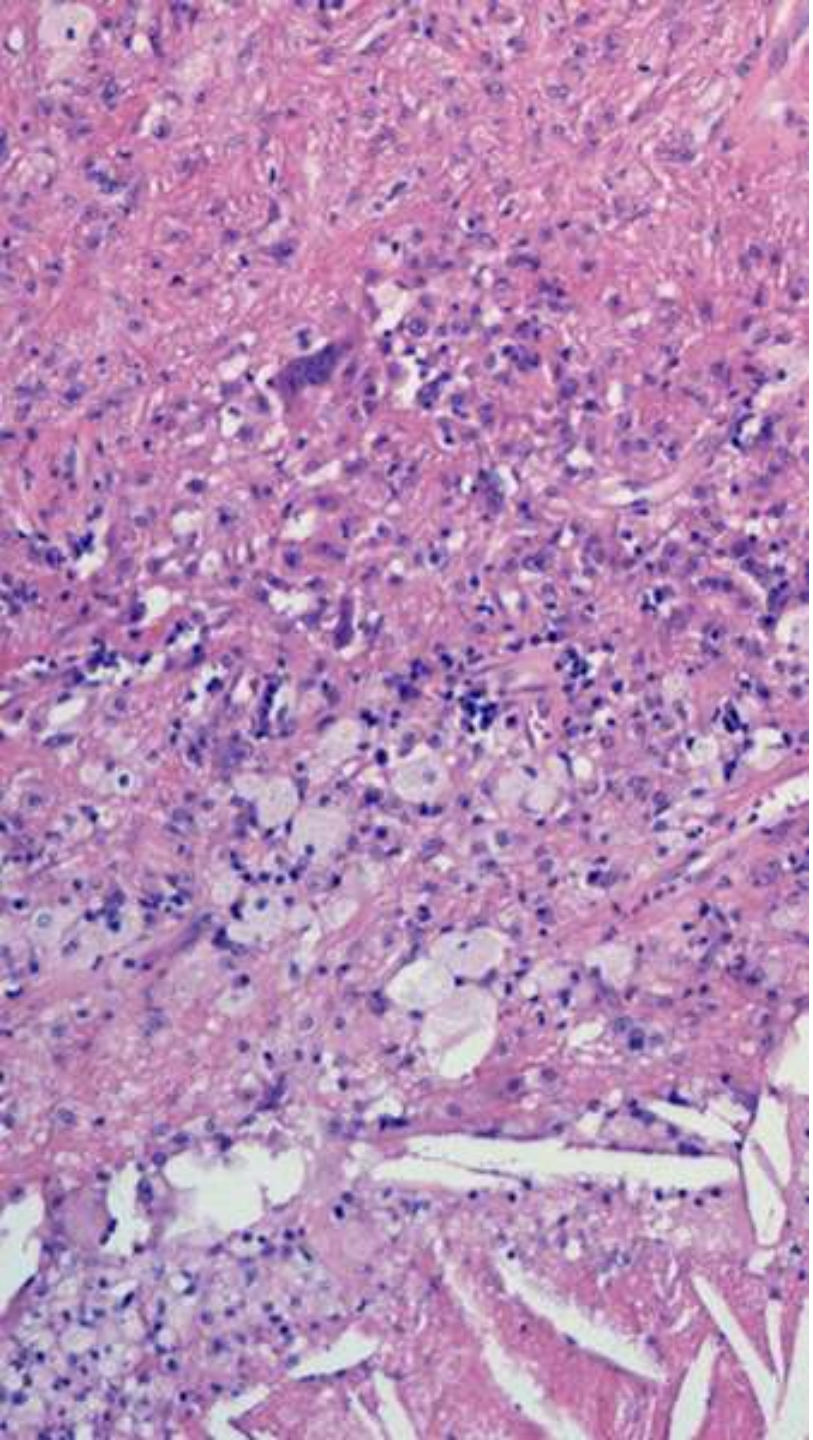

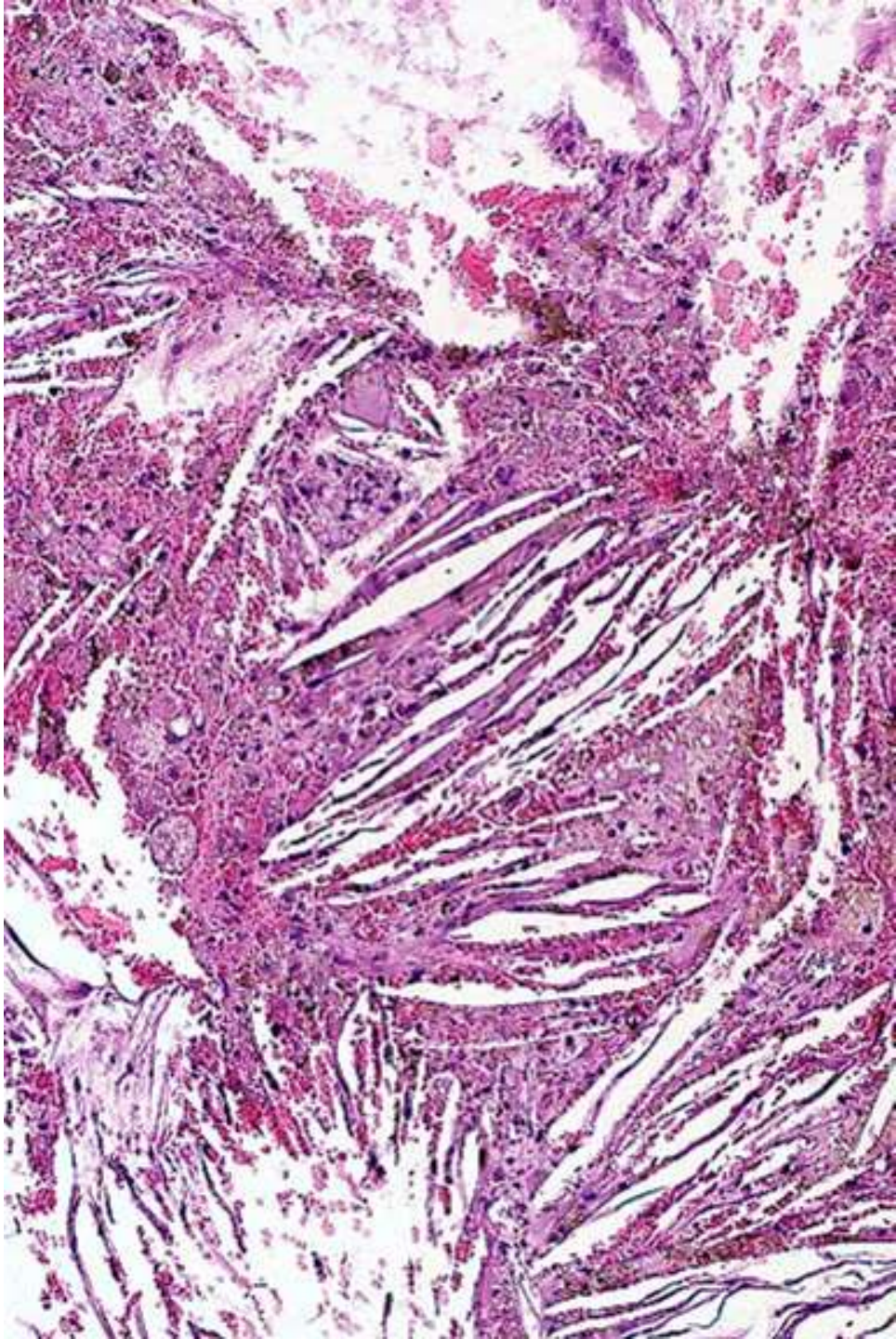

Fatty changes could also see in the breast, kidney and skeletal muscles.

_ ***Accumulations may involve cholesterol and its esters within:***

1. ***Smooth muscles cells and macrophages*** those are located within the intima of the arteries in ***Atherosclerosis***

2. Macrophages in the acquired and hereditary hyperlipidemia. In such case the accumulation are usually seen within the subcutaneous connective tissue of the skin and in tendons producing masses known as ***Xanthomas.***

Pigmentation:

Definition: - Its others form of degenerations; pigments are colored substance and are either

_ ***Normal*** constituent of the body e.g. melanin or

_ ***Abnormal*** pigment that are accumulated under certain situations.

These pigments are either:

1. Endogenous pigmentation. Or

2. Exogenous pigmentation.



Endogenous Pigmentation:

1. Lipofucin pigment.
2. Melanine pigment.
3. Derivative of hemoglobin (***hemosiderin*** and ***bilirubin***).

Lipofucin pigment (Lipochrome pigment):

This is a ***yellow-brown***, ***intra-cytoplasmic pigment***, which is seen in cells undergoing slow atrophy. Its

1. Particularly prominent in the cells of ***liver*** and ***heart*** of the ***elderly*** (brown atrophy of the heart).
2. Patient with ***sever malnutrition*** and ***cancer cachexia.***

Melanin pigment:

This is an ***endogenous***, ***non-hemoglobin derived***, ***brown-black pigment***. This skin pigment is produce by the oxidation of tyrosine through the help of enzyme tyrosinase within melanocytes.



Hemosiderin pigment:

This is a ***hemoglobin-derived***, ***golden-yellow to brown granules***.Exessive iron in the body cause hemosiderin to accumulate within the cells. Excessive deposition of hemosidrein is termed (***Hemosiderosis).***

Hemosiderosis could be either ***localized*** or ***generalized*** (systemic).

_***Localized Hemosiderosis*** usually result from ***local hemorrhage*** e.g. the common bruise, pulmonary or cerebral hemorrhage.

_***Systemic Hemosiderosis*** occur whenever there is ***systemic iron overloud***, here the deposition is seen in many organs and tissues such as the liver .This is associated with

1. Increased absorption of iron.
2. Impaired utilization of the iron.
3. Hemolytic anemia.
4. Excessive blood transfusion.

HEMOSIDERIN/MELANIN/ETC.

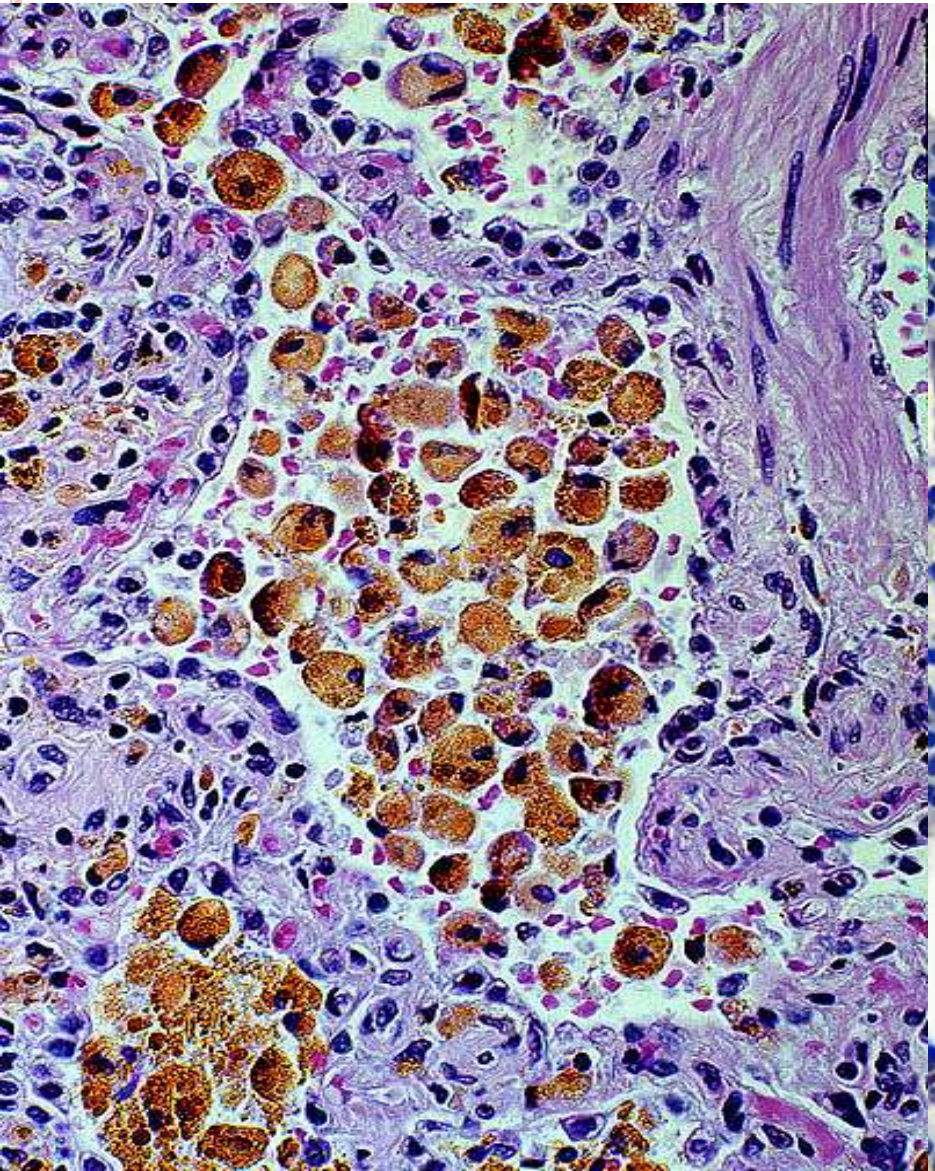

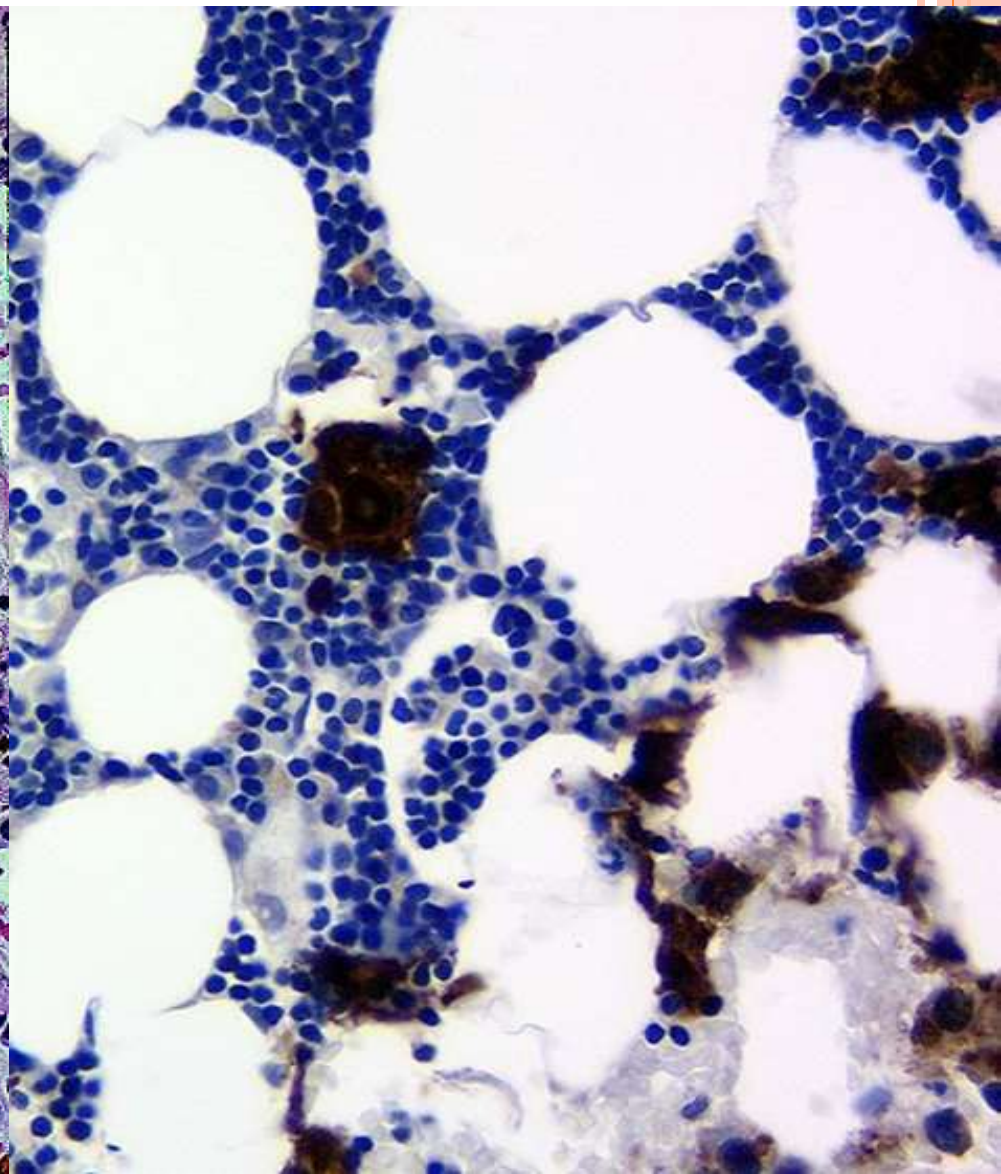

- In systemic Hemosiderosis, hemosiderin accumulated ***first*** within ***reticulo-endothelial cells*** of various organs and tissues with progressions accumulation seen in the ***parenchymal cell principally of liver, pancreas, heart and endocrine organ.***
- In most instance the accumulated hemosiderin does not damage the parenchymal cell however in the more extreme accumulation (as seen in haechromatosis) there are associated liver and pancreatic damage resulting in liver cirrhosis and diabetes mellitus

Bilirubin pigment:

This is a normal major pigment of bile, which is derived from hemoglobin (but contains no iron), the conversion of bile occur within hepatocytes.

Jaundice results from excessive bilirubin pigments that are distributed through out all tissues and body fluids.

In the liver, particularly when there is obstruction to the bile flow (e.g. obstruction of the common bile duct by stone, tumor or biliary atresia), bilirubin is seen within bile canaliculi, kuppfer cells and hepatocytes as green-brown globular deposits. This gives greenish color to the liver.

Exogenous Pigmentation:

The usual routs of administration of exogenous pigmentation are by:

1. Inhalation.
2. Ingestion.
3. Injections.

Types of exogenous pigmentations:

1. Carbon pigment (coal dust):

It's the most common ***exogenous pigment***. When this pigment inhaled, its pickup by macrophage within the alveoli then transported via lymphatic to regional lymph nodes in the hila of the lungs.

Accumulations of this carbon pigment cause black discoloration of the lung tissues,

A condition called ***anthracosis.***

In coal miners and those living in heavily polluted atmosphere, the deposition may be very marked and associated with fibrosis and emphysema, a condition called ***coal workers pneumoconiosis.***



ANTHRACOSIS





2. Tattooing: Its form of ***exogenous pigmentation*** of the skin. The pigment inoculated is taken up by dermal macrophage.

3. Silicosis: Occur due to inhalation of silica particles.

4. Siderosis: Its rare pigment, occur due to injection of excessive amount of iron.



TATTOO. MICROSCOPIC

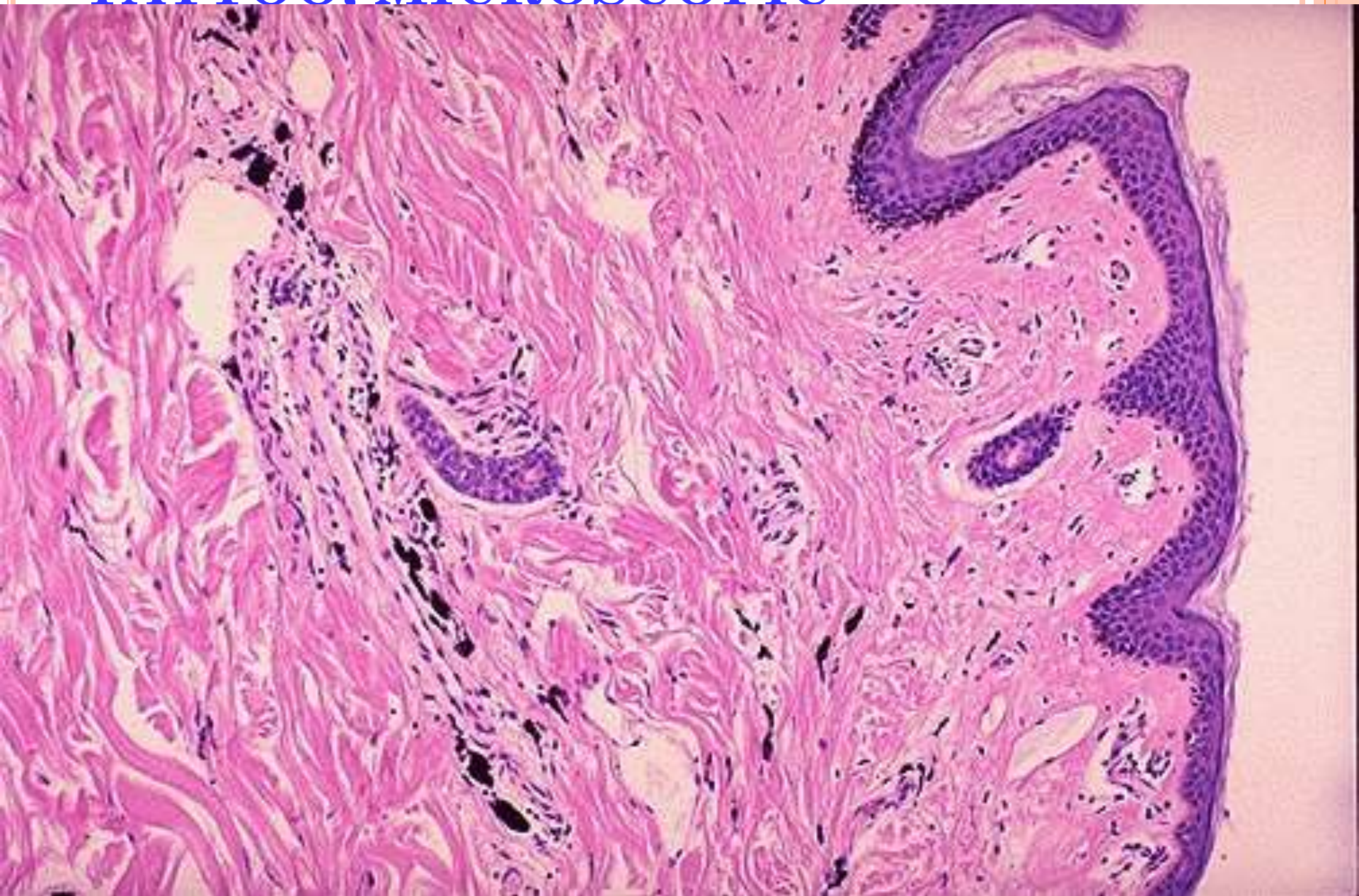

Cellular Adaptations:

These reactions are induced by physiological or pathological stimuli; the aim is to escape cell injury.

The adaptive responses include:

1. Atrophy.
2. Hyper atrophy.
3. Hyperplasia.
4. Metaplasia.
5. Dysplasia.



1. Atrophy:

This refers to a decrease in the size of the cell by loss of cell substance. When sufficient numbers of cells are involved, the entire organ or tissue decrease in size (i.e. become atrophic).

Causes of atrophy include:

1. ***Decrease workload*** e.g. muscular atrophy due to immobilization as in fractured limb.
2. ***Denervation*** (loss of nerve supply) e.g. paralysis of a limb due to nerve injury or poliomyelitis.
3. ***Ischemia*** e.g. brain atrophy as an ageing phenomena due to atherosclerosis.
4. ***under nutrition*** as in starvation and kwashiorkor.
5. ***Deficiency of endocrine system*** e.g. atrophies of the gonads in hypopituitarism and senile endometrial atrophy (decrease estrogen secretion from the ovary).

The aim of this adaptation (atrophy) is to bring into balance cell survived in the face of reduced blood supply ,nutrition , etc…,the cell become smaller with diminished function all thus reduced metabolic needs and by doing so they escape injury. The reduction in size is due to reduction in number of its structural components e.g. mitochondria, myofilament, endoplasmic reticulum, etc……

Because of the above, cell debris accumulated, some cell resist digestion by intracellular enzymes and become enclosed by a membrane (residual body) e.g. Lipofucin granules .When latter is present in sufficient amount, its imparts brown discoloration to the affected tissues (brown atrophy of the heart)

If the cause is sever or persistent, the atrophic cell gets injured and eventually dies to be replaced by fibrosis



2. Hyper trophy:

This refers to increase in the size of cell and as a consequence the size of organ or tissue containing them (i.e. apposite to the atrophy).

It's due to synthesis of the more structural components within the cell (more enzymes, more mitochondria and more myofilament, etc…….).

Causes of hypertrophy include:

It could be either:

1. Physiological. Or
2. Pathological.

Examples include:

1. Uterus in pregnancy. (Physiological: hormonal).
2. Skeletal muscles in athletes (physiological: increased workload).
3. Left ventricle in systemic hypertension (pathological: increase workload: here the ventricle has to contract against increase pressure in the aorta).



The excessive workload induce increase in cellular constituent i.e. more enzymes, more mitochondria (ATP production), and more myelofilaments.

The aim is to achieve equilibrium between the demand and the cells functional capacity, if the burden persists, the hyper trophy reached a limit beyond which the enlarged muscles is no longer able to compensate for the increased work and cardiac failure will occur, at this point there is lyses and loss of myofibrils contractile elements.

HYPER-TROPHY

IN-CREASE IN SIZE OF CELLS



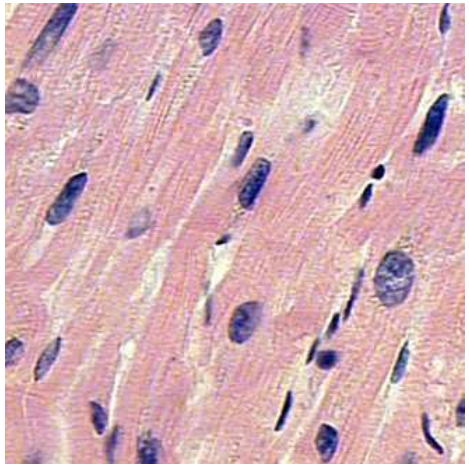



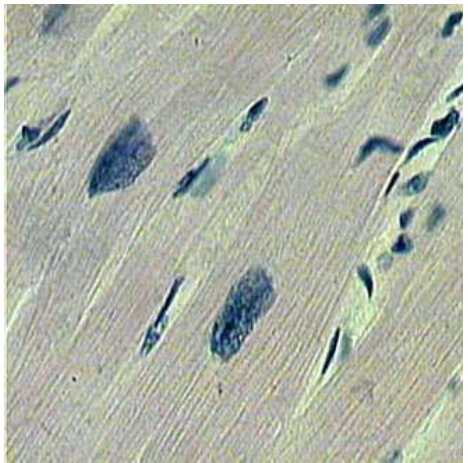

3. Hyperplasia:

This refers to increase in the number of the cells in an organ or tissue leading to an increase in size.

Hyperplasia a hyper trophy are closely related and often occur together (e.g. estrogen induced enlargement of the uterus during pregnancy; there is both hyperplasia and hyper trophy of the myometrium).

Note: not all adult cell types have the same capacity for hyperplasia, those capable of cell division called ***labile cells*** can undergo profound hyper plastic growth e.g. those of epidermis, mucosal surface, hepatocytes, fibroblast and B.M cells).

On the contrary, nerve cells and those of the heart (myocardial cells) and skeletal muscles fiber have no capacity for hyperplasia so it's called ***Permanent cells.***

Intermediate among the above two are those of the bone, cartilage, and smooth muscles cells.

Cause of hyperplasia:

It could be either:

A. Physiological.

B. Pathological.

A. Physiological: It's either due to:

1. Hormonal: e.g. proliferation of the breast glandular epithelium in female at puberty or during pregnancy.

2. Compensatory: e.g. after partial hepatectomy

B. Pathological: It's either due to:

1. Excessive hormonal stimulation: e.g. endometrial hyperplasia.

2. The effect of growth factors on targets cells as in wound healing.



4. Metaplasia:

This refers to replacement of one mature cell type by another mature cell type. It may represent an adaptation of cells more sensitive to stress by other cells that are more resistant to adverse environment e.g. include:

1. Squamous Metaplasia of laryngeal and bronchial respiratory epithelium due to habitual smoking.
2. Squamous Metaplasia of the urothelium in the urinary bladder due to bilharzias or vesical stone.
3. Columnar Metaplasia of the esophageal Squamous epithelium as a result prolong reflux of acidic gastric juice into the esophagus.



5. Dysplasia:

This refers to disturbed proliferations of the cells associated with a typical

Cytological changes that involve cell size, shape, and organization.

It's not an adaptive process but considered here because of its closed relation to hyperplasia. It's most commonly encountered in lining epithelium, mostly Squamous e.g. that of respiratory passages (i.e. in habitual smoker). The increase proliferation activity produce greater amount of DNA and thus the nuclei appear more hyper chromatic.

Although there is an increase in mitotic activity, there is usually no abnormal mitosis. The letter is usually met with cancerous stages.

Dysplastic changes are often found adjacent to the foci of cancer indicating that it is a stage that proceeds development of frank malignancy, however dysplasia dose not necessary progress to cancer.



Calcification:

Definition:-This refers to abnormal deposition of calcium salts. There are two forms of calcification:

1. Dystrophic Calcification: Refers to calcium deposition in non-viable or drying tissues that occurs despite normal serum calcium levels and the absence of any derangement in calcium metabolism.

2. Metastatic Calcification: It signifies deposition of calcium in viable tissue, almost always a reflection of some derangement in calcium metabolism that lead to hypercalcaemia (i.e. increase serum calcium level).

1. So in ***metastatic calcification***, usually there is ***hypercalcaemia*** and the ***calcium is deposited in normal tissues***. Kidney, skeletal muscles, skin, lung, etc…..
2.
3. The causes of increased level of calcium in the serum include:
4. 1. Hyper-parathyrodism.
5. 2. Breakdown of bony tissues such as in Osteoporosis.
6. 3. Hypervitemenosis D. due to over dose of vitamin D.
7.



- While in ***dystrophic calcifications*** here the level of serum calcium is ***normal***, usually calcium deposited in ***non-viable tissues***. It's noted in:
- 1. Area of necrosis (whether Coagulative, caseaus, Liquefactive or fat necrosis)
- 2. Advanced atherosclerosis.
- 3. Damage or ageing heart valve.
-
-

Grossly: The calcification is seen as fine, white granules or clumps giving gritty feeling.

Microscopically: Its appears as basophilic (bluish), amorphous granules that may coalesce to form larger clumps.

Amyloidosis:

Definition:-This refers to deposition of amyloid substances in the ***extra-cellular*** compartments of the tissues. It's an ***abnormal protein***. Amyloid means ***starch-like*** substances.

Pathogenesis:

An amyloid substance is un soluble material and it's also resistance to digestion by proteolytic enzymes, therefore amyloid deposition in the tissues is permanent and this will cause disability to the tissues and to the patient.

Amyloid is deposited in extra cellular compartments and it's mainly seen in the wall of small blood vessels.

Amyloid depositions cause disability through following mechanisms:

1. It interferes with exchanges of solute between blood and tissues cell.
2. It will cause pressure atrophy on the cells.
3. It interfere mechanically with contraction of myocardial and smooth muscles fibers.

- ***Effects of amyloidosis:***
  Macroscopical effects: Usually the effected organs are large in size ,
- firm, lose of elasticity, the cut section of organ is waxy and transparent .
- ***Microscopical effects:*** Amyloid substance is homogenous (not granular,(
  A cellular, structurless, eosinophilic with pale pink color material .
- If deposition of amyloid is little, the effect also will be little so it may case for e.g. slight damage to the glomeruli casing proteinuria,also, also little deposition in the wall of blood vessels make them susceptible to the trauma and they bleed easily causing petechial hemorrhage .
- If deposition occur in large amount, e.g. in the liver cause hepatomegaly .

- ***Diagnosis and demonstration of amyloidosis :***
- ***.1Lugol's Iodine:*** Amyloid has affinity for iodine so when Lugol's iodine solution is poured over tissue; the amyloid is stain deep brown in contrast to normal tissue which is only slightly stained .
- ***.2Congo Red Stain:*** This stain may used on gross specimen and section for microscopy .
- _In polarized light, amyloid stain by Congo red show a green birefringence and this is the most reliable technique used for demonstration of amyloidosis .
- ***.3Rosaniline dyes:*** These include gentian violet, methyl violet, and crystal violet .

- ***.Fluorescent dyes:*** Thioflavine-T binds to amyloid and its presence is demonstrated by fluorescent microscopy. It give yellow color to the amyloid substance .The reaction is not however, entirely specific for amyloid .
- ***.5Immuno-histochemical technique:***
  .6Electron microscope: This is the most characteristic and diagnostic
- feature of amyloid .



Classification of amyloidosis:

.1According to the chemical compositions :

Either its:

A. Fibrous protein: This is of two types either :

.1AL protein (which is called L-amyloid). 2. AA protein (which is called A-amyloid .(

B. Non-fibrous protein.



2.According to the underlying etiology:

A. systemic: This is either A. Primary. Or B. Secondary.

B. Localized:

C. Genetically determined:



A. systemic: Either its

.1Primary amyloidosis :

-Here there is no predisposing factors, its usually seen in malignant disease of the plasma cells, the disease is called multiple myeloma or in monoclonalgammopathy .

-Here the rectal biopsy is positive in most of cases, the cause of death either heart or renal failure .



2.Secondary amyloidosis :

-Here there is always predisposing factors for this type. -Its mainly effect the liver, spleen, kidney and adrenal gland. - Here rectal biopsy is positive in about 80 % of cases. -Predisposing factors include the following :

.1Rheumatoid arthritis.
.2Chronic osteomalesia.
.3 Bronchiostasis.
.4Chronic tuberculosis.
.5Chronic pyelonephrities.
.6 Leprosy .
.7Syphilis.
.8Hodgkin's disease .

B. Localized :

The tissue mass or masses composed of amyloid tissue may be present in one organ; here there is also no predisposing factor they appear as large mass of amyloid tissue in one organ like skin, bronchi, lung, heart, urinary bladder and thyroid gland .



- ***C. Genetically determined:*** It's either :
- .1Autosomal recessive.
- .2 Autosomal dominant .




THANK
YOU!