

ELECTRICITY WITHIN THE BODY

Electricity is everywhere, even in the human body. Our cells are specialized to conduct electrical currents.

Electricity is required for the nervous system to send signals throughout the body and to the brain, making it possible for us to move, think and feel.

how do cells control electrical currents?

The elements in our bodies, like sodium, potassium, calcium, and magnesium, have a specific electrical charge. Almost all of our cells can use these charged elements, called ions, to generate electricity.

the important role of electricity in health and disease.

A disruption in electrical currents can lead to illness. For example, in order for the heart to pump, cells must generate electrical currents that allow the heart muscle to contract at the right time. Doctors can even observe these electrical pulses in the heart using a machine, called an electrocardiogram or ECG. Irregular electrical currents can prevent heart muscles from contracting correctly, leading to a heart attack

The nervous system can be divided in two parts.

1-Central nervous system consists of the

-brain

-spinal cord

-nerve fibers (neurons)

That transmits sensory information to brain or spinal cord and from brain or spinal cord to appropriate muscles and glands.

2-The autonomic nervous system

Controls various internal organs such as the heart, intestines, and glands.

The basic structural unit of the nervous system is a neuron (Fig 1).

A nerve cell specialized for the

-reception

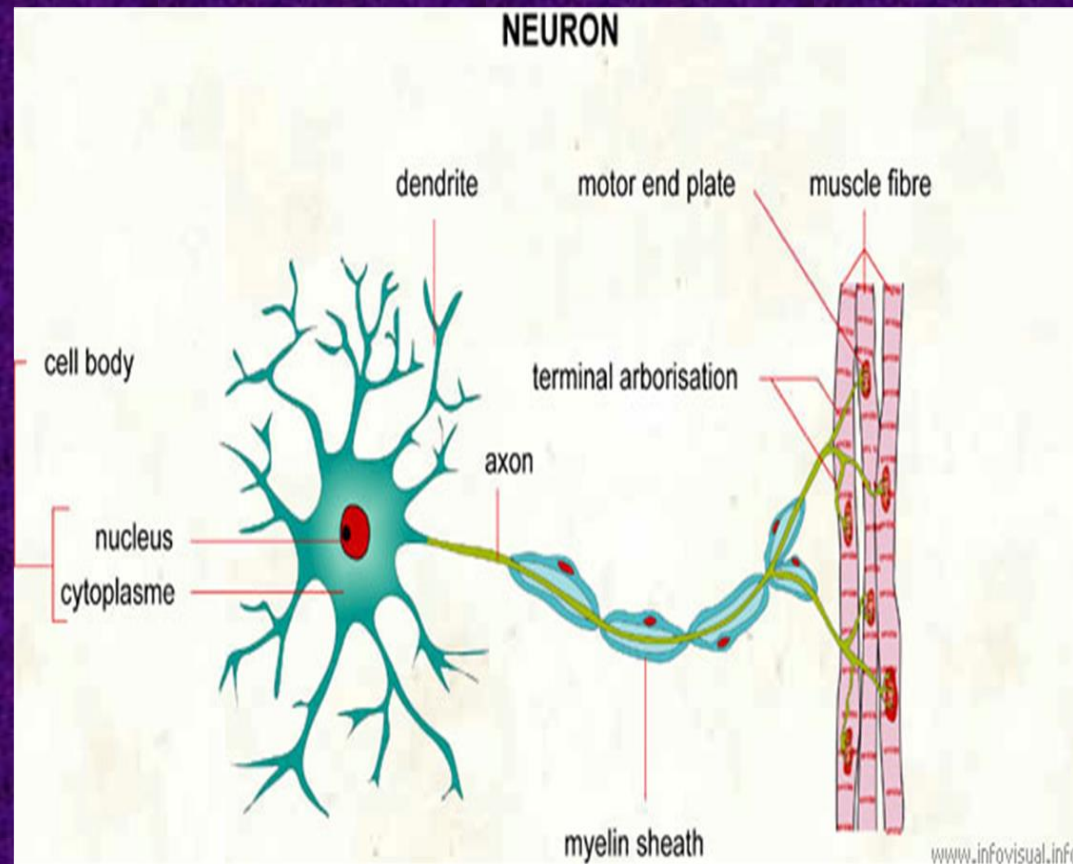
-interpretation

-transmission of the electrical messages

THE NERVOUS SYSTEM AND THE NEURON

Neuron consists of a cell body that receives electrical messages from other neurons through contacts called synapses located on the dendrites. The neuron transmits an electrical signal out word along axon. The axon carries the electrical signal to muscle, gland, or other neuron

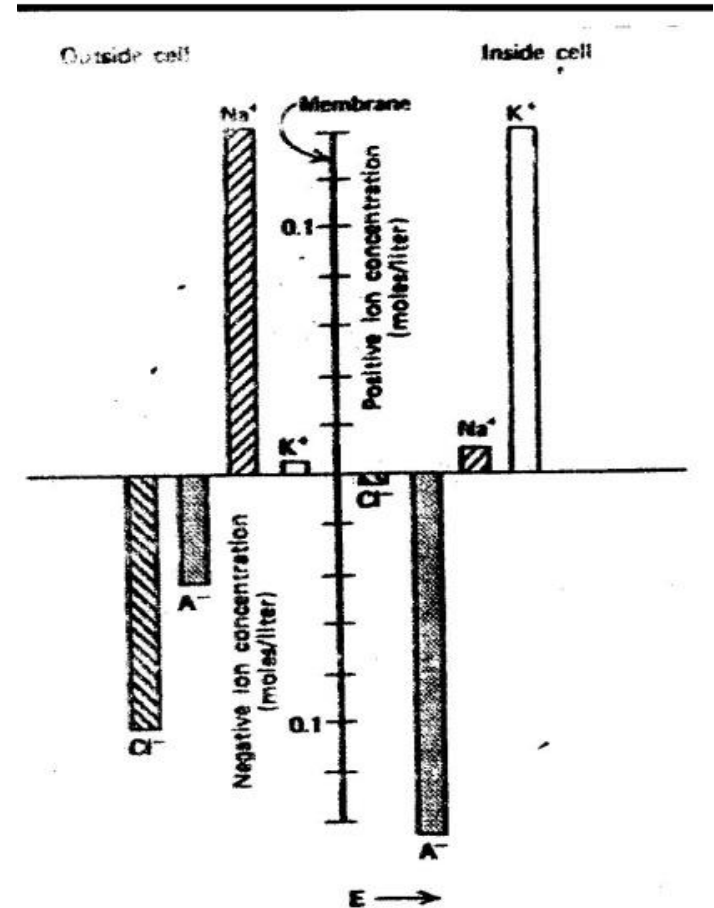
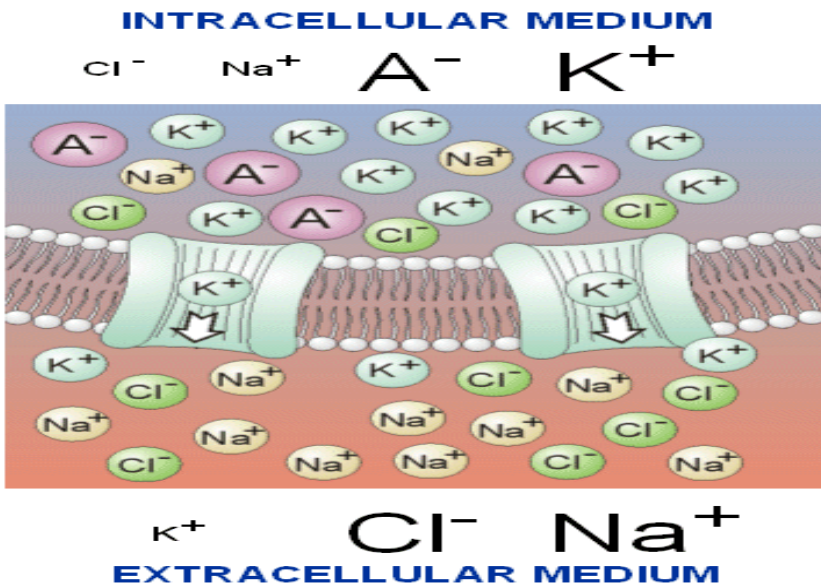
• Fig 1 Basic structural unit of the nervous system



2-ELECTRICAL POTENTIALS OF NERVES

A cross the surface or membrane of every neuron is an electrical potential difference due to the presence of more negative ions on the inside of the membrane than the outside , the neuron said to be polarized , the inside of the cell is typically 60 -90 mv more negative than outside.

The potential difference is called the resting potential of the neuron. (Fig 2) the typical concentrations of various ions inside and outside the membrane of an axon •



When the neuron is stimulated a large momentary change in the resting potential occurs at the point of stimulation. This potential change called action potential propagates along axon. The action potential is the major method of transmission of signals within the body. The stimulation may be caused various physical and chemical stimuli such as heat, light, sound, and others. We can explain the resting potential by using a model in which membrane separates a concentrated neutral solution of KCl. The KCl in solution forms K^+ ions and Cl^- ions

We assume that membrane permits K^+ ions pass through it but does not permit the passage of Cl^- ions. The K^+ ions diffuse from the high concentration region (H) to low concentration region (L). This movement results in an excess of positive charge in (L) and excess of negative charge in (H). These charges form layers on the membrane to produce an electrical force that retards the flow of K^+ ions from H to

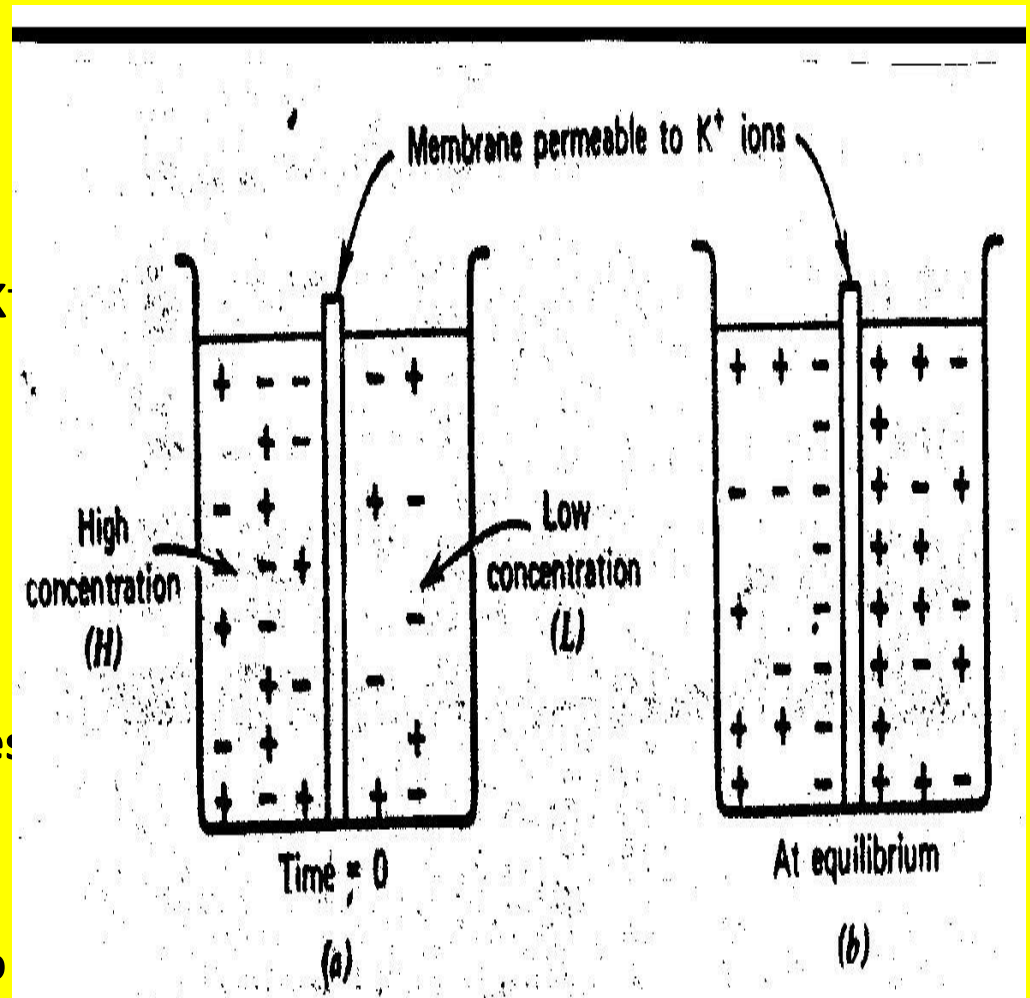


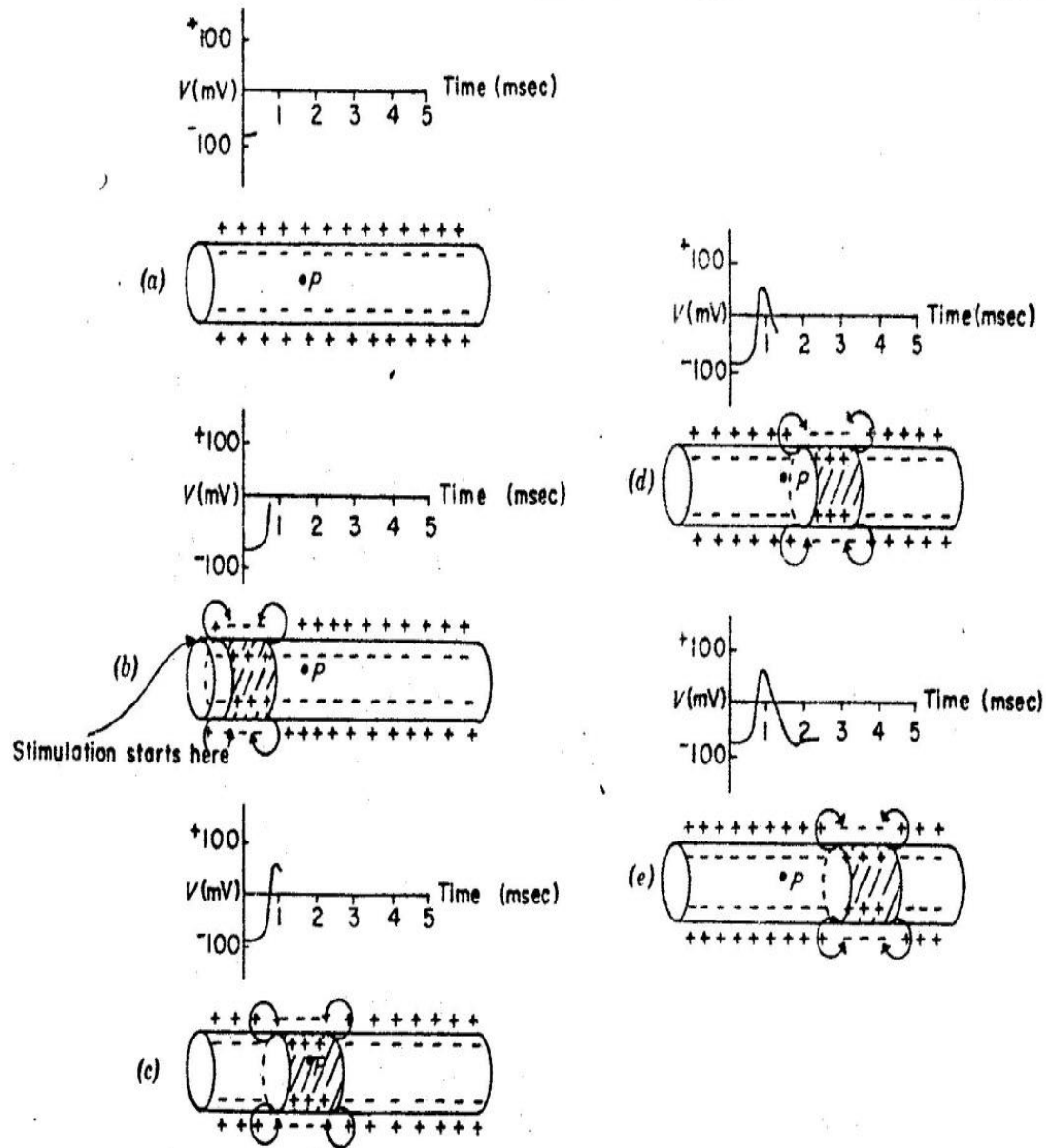
Fig 3 Model of the resting potential1

(Fig 4) shows potential measured between point P and the outside of the axon.

a-The axon has rest potential of about -80 mv (Fig a)

b-If the left end of the axon is stimulated the Na^+ ions pass through the membrane. Causing it to depolarize. The inside momentary goes positive to about 50 mv.

c-The positive current flow on the leading edge, indicated by the arrows, stimulates the regions to the right so that depolarization takes place and potential change propagates (d and e), meanwhile K^+ ions move out of the axon and restore the resting potential (repolarize the membrane).



ELECTRICAL SIGNALS MUSCLES –ELECTROMYOGRAM

The transmission of the action potential from the axon into the muscle, where it causes muscle contraction. The record of potentials from the muscle during movement is called the electromyogram or EMG.

A muscle is made up of many motor units. A motor unit consists of a single branching neuron from brain or spinal cord and the 25 – 2000 muscle fibers (cells) it connect to motor end plates (Fig 5a).

The action potential travels along an axon and is transmitted across the motor end plates into the muscle fibers causing them to contract. The record of the action potential in a single muscle cell is shown in (Fig 5b). EMG electrodes usually record the electrical activity from several fibers, and needle electrode inserted under the skin measures single motor unit activity, electrically stimulating the motor units, it is possible to excite the sensory nerves that carry information to central nervous system. The reflex system can be studied by observing the reflex response at the muscle.

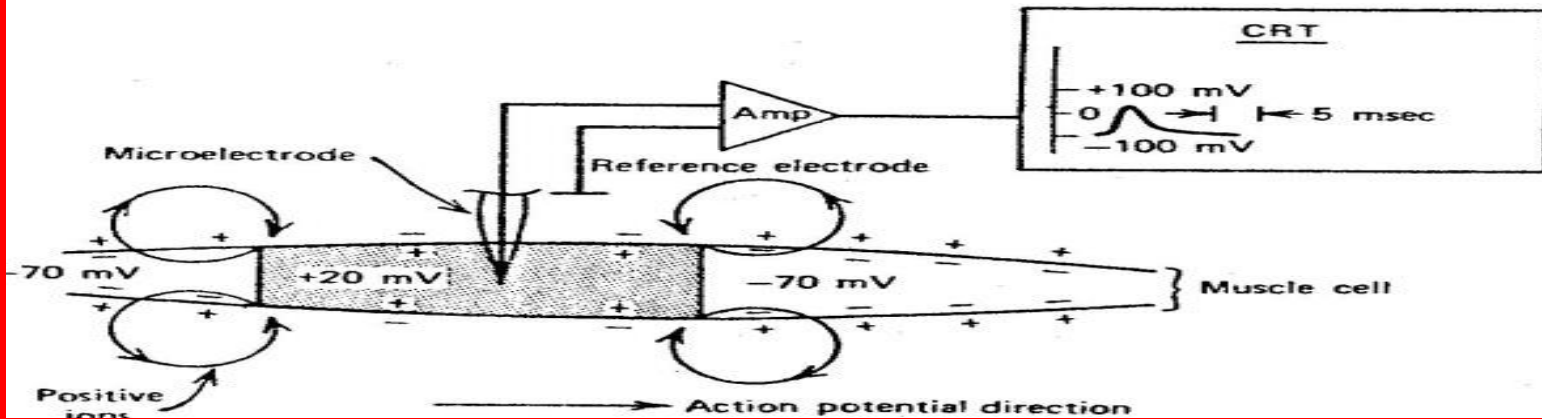
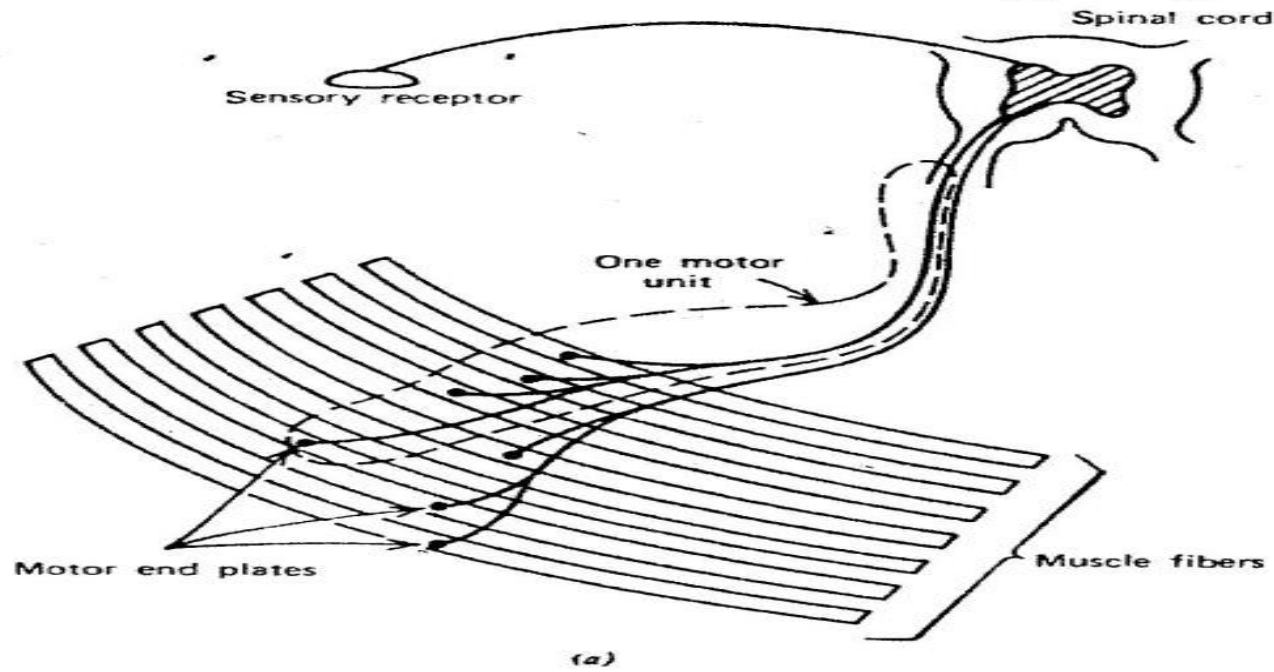


Fig 5

ELECTRICAL SIGNALS FROM THE HEART-ELECTROCARDIOGRAM

- The rhythmical action of the heart is controlled by an electrical signal initiated by spontaneous stimulation of special muscle cells located in the right atrium. These cells make up the *sinoatrial (SA) node* or the pacemaker.

The electrical signal from SA node initiates the depolarization of the nerves and muscles of both atria, causing the atria to contract and pump blood into ventricles. Repolarization of the atria follows. The electrical signal then passes into the atrioventricular (AV) node, which initiates the depolarization of the right and left ventricles. Causing them to contract and force blood into the pulmonary and general circulation. The ventricle nerves and muscles then repolarize and sequence begins again.

The relationship between the pumping action of the heart and electrical potentials on the skin can be understood by considering the propagation of an action potential in the wall of the heart.

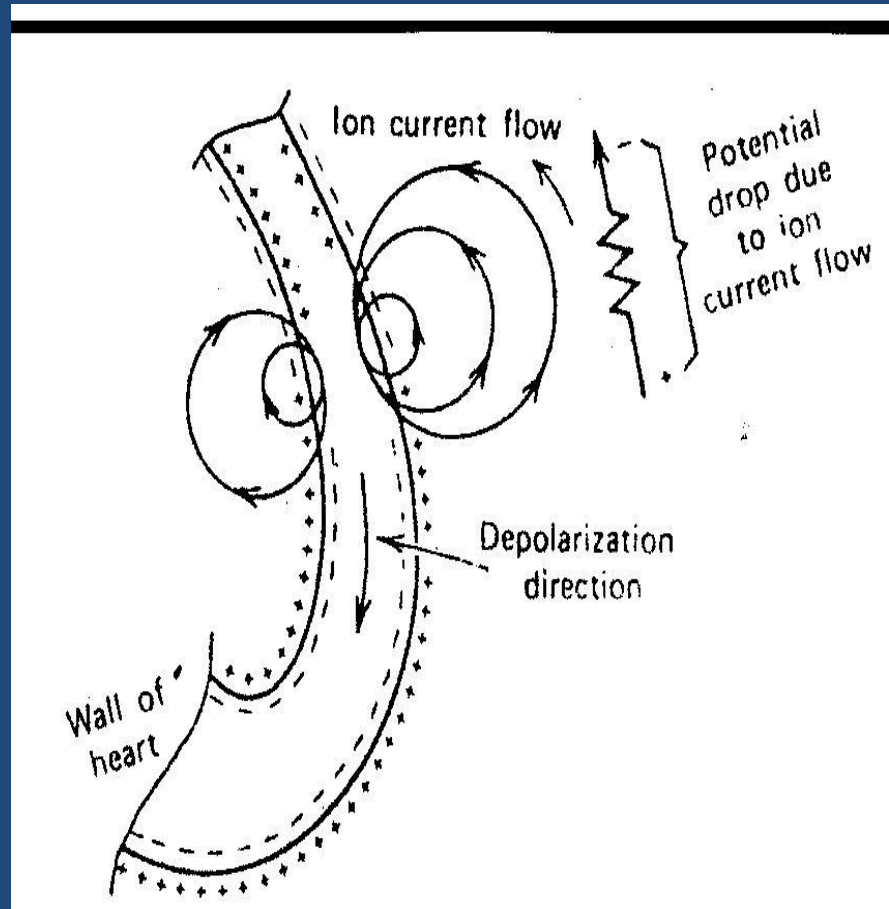


Fig 6 Schematic of an action potential moving down the wall of the heart

Action potential moving down the wall of the heart some of ion current indicated by circles, passes through torso, indicated by the resistor. The potential on the chest wall is due to current flow through the resistance of torso.

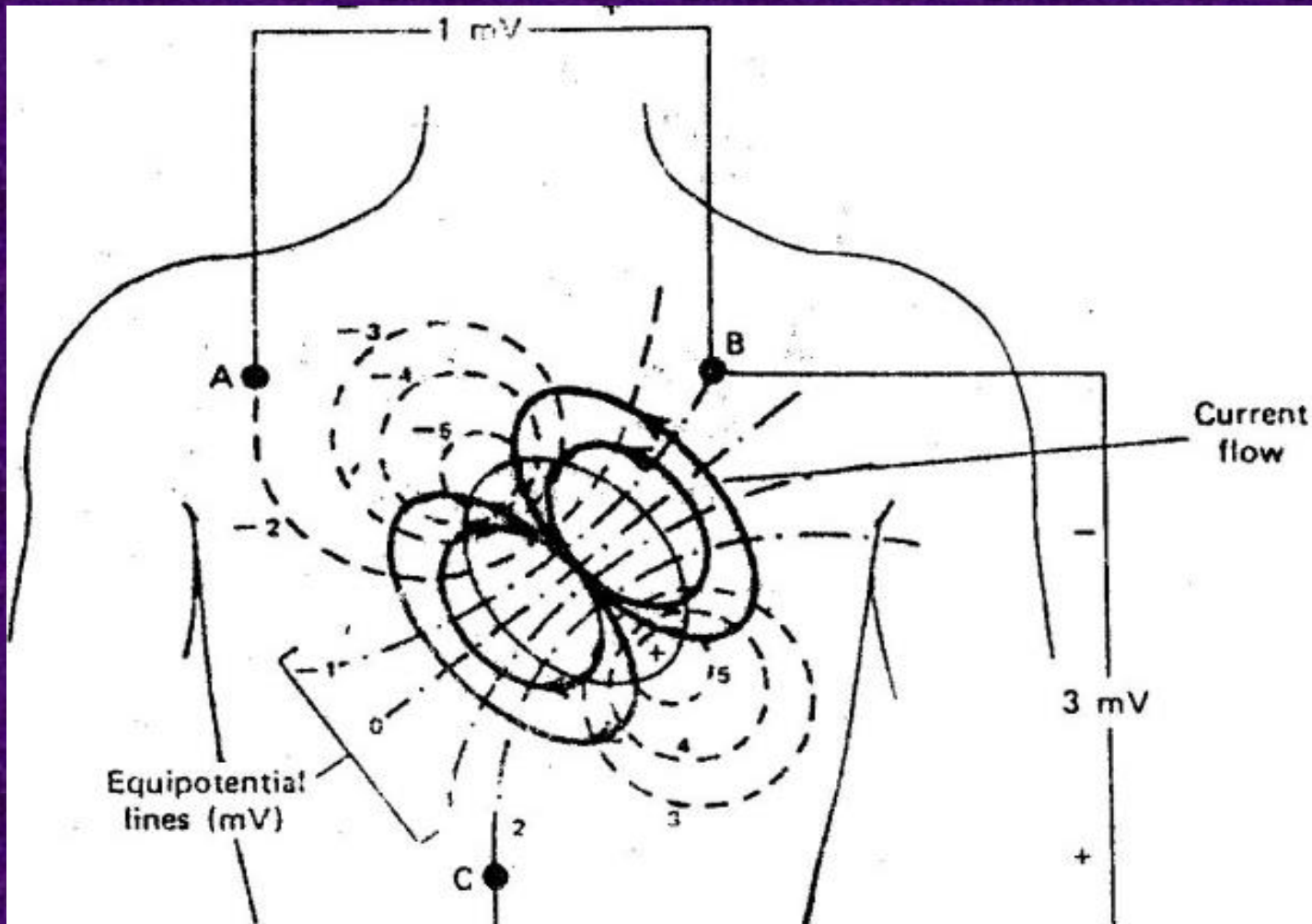


Fig 7. The potential distribution on the chest at the moment when the ventricles are one –half depolarization

The potential distribution on the chest when the ventricles are one-half depolarized by equipotential measured on the surface of the body depend upon the location of the electrodes for obtaining the ECG located on the left arm(LA), right arm (RA), and left leg (LL).

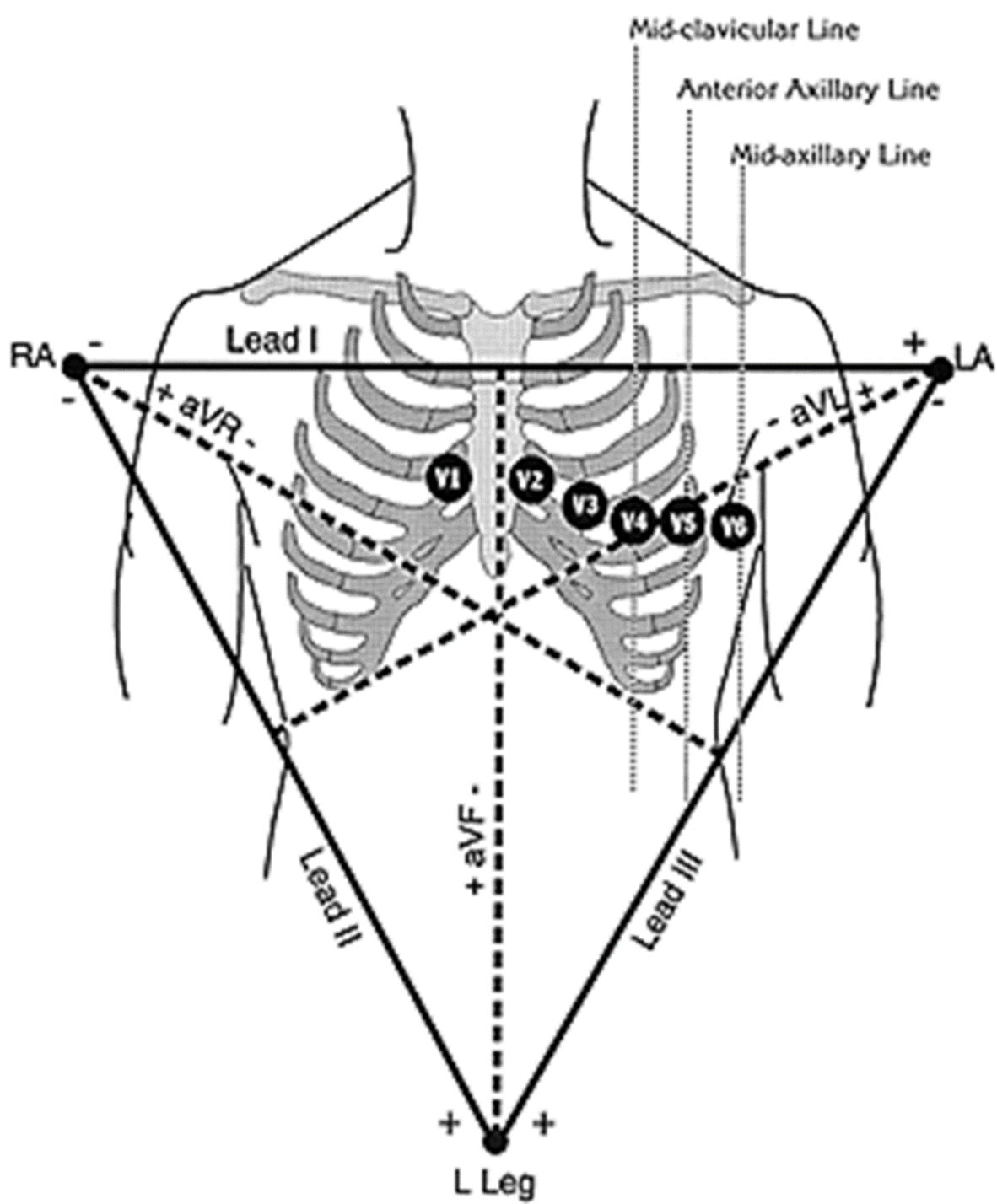
The measurement of the potential between RA and LA is called Lead I

The measurement of the potential between RA and LL is called Lead II

The measurement of the potential between LA and LL is called Lead III

The potential between any two gives relative amplitude and direction of the electric dipole vector in the frontal plane. Three augmented lead configurations, aV_R , aV_L , aV_F . For the aV_R lead, one side of the recorder is connected to RA and other side is connected to the center of two resistors to LL and LA, and aV_L lead, the recorder is attached to the LA electrode and the resistors are connected to RA and LL.

For aV_F , the recorder is attached to LL the electrode and the resistors are connected to RA and LA.



activity of the heart, through each part of its cycle. The major electrical events of the normal cycle are.

1-The atrial depolarization, which produce the P wave.

2-The atrial repolarization, Which is rarely seen and is unlabeled.

3-The ventricular depolarization, which produce QRS complex.

4-The ventricular repolarization, which produces T wave.

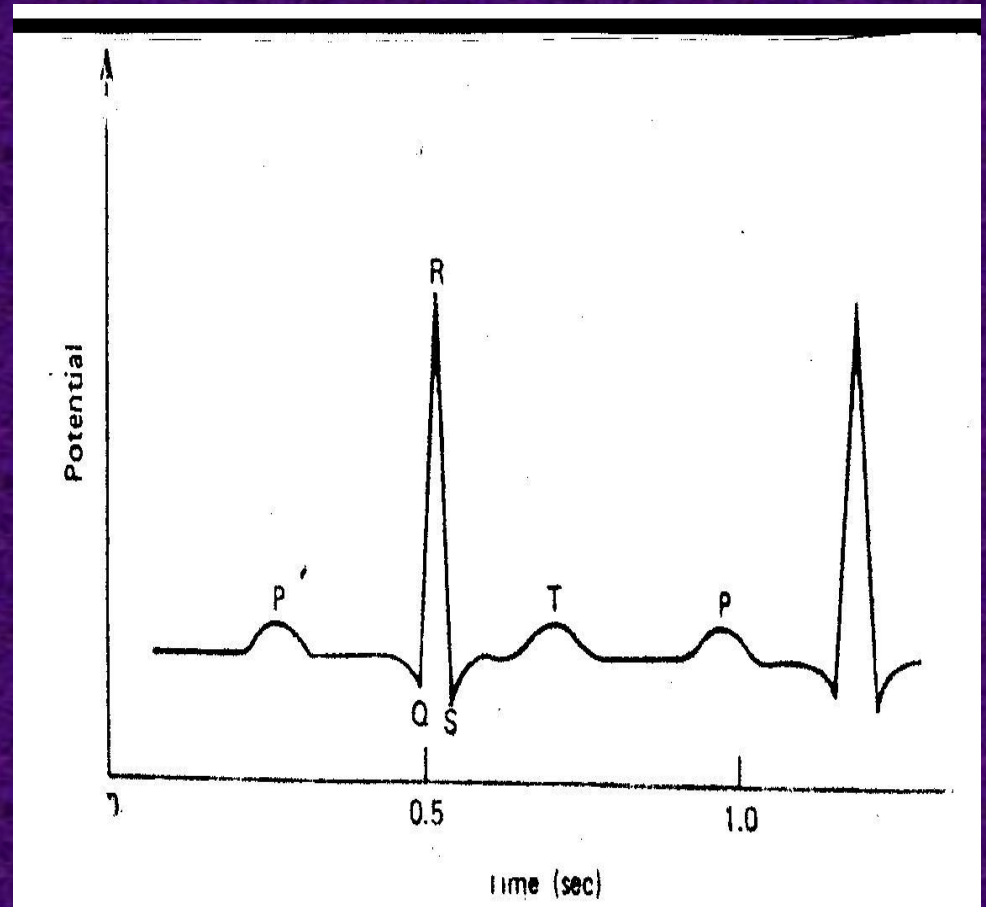
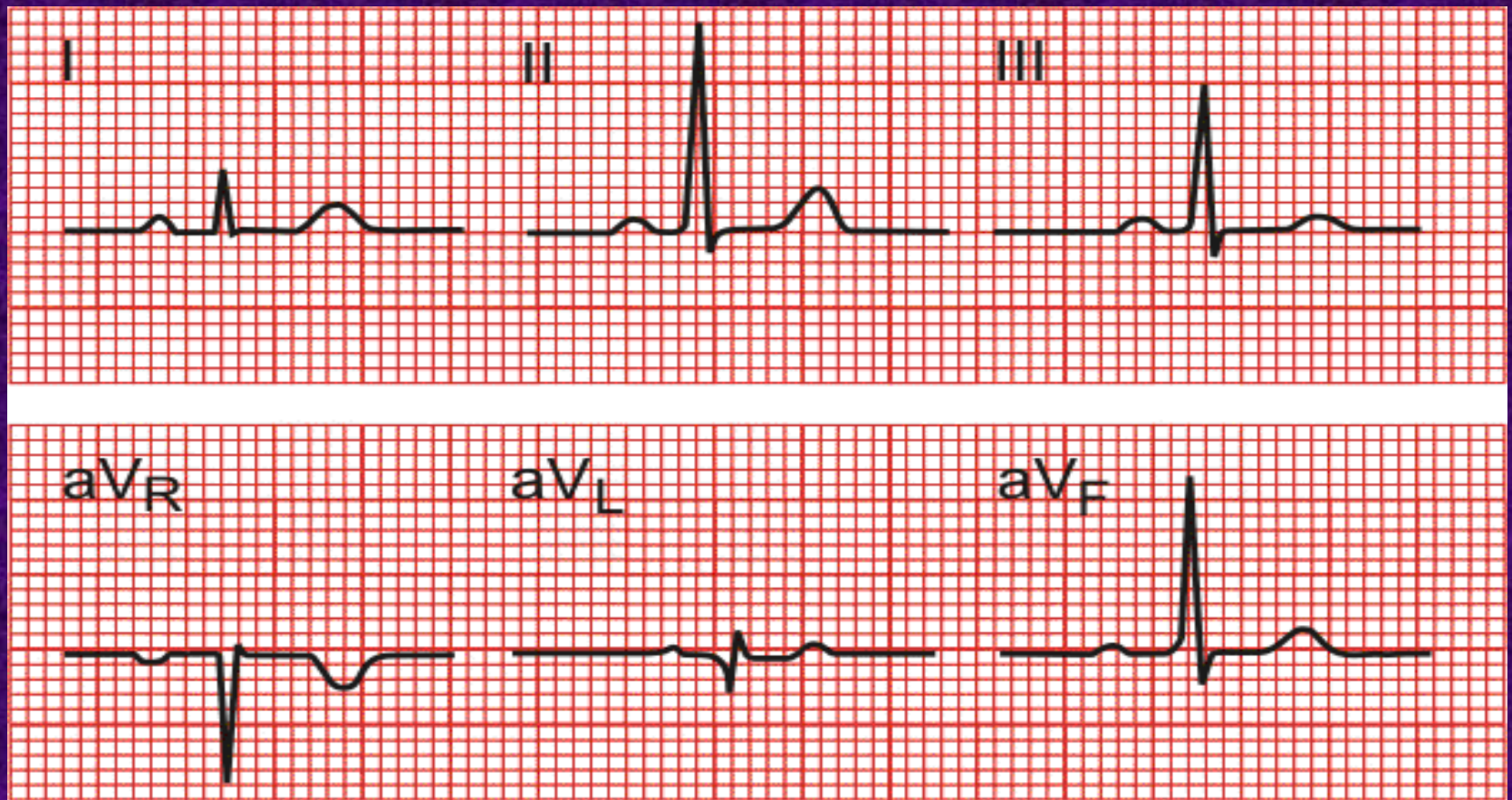
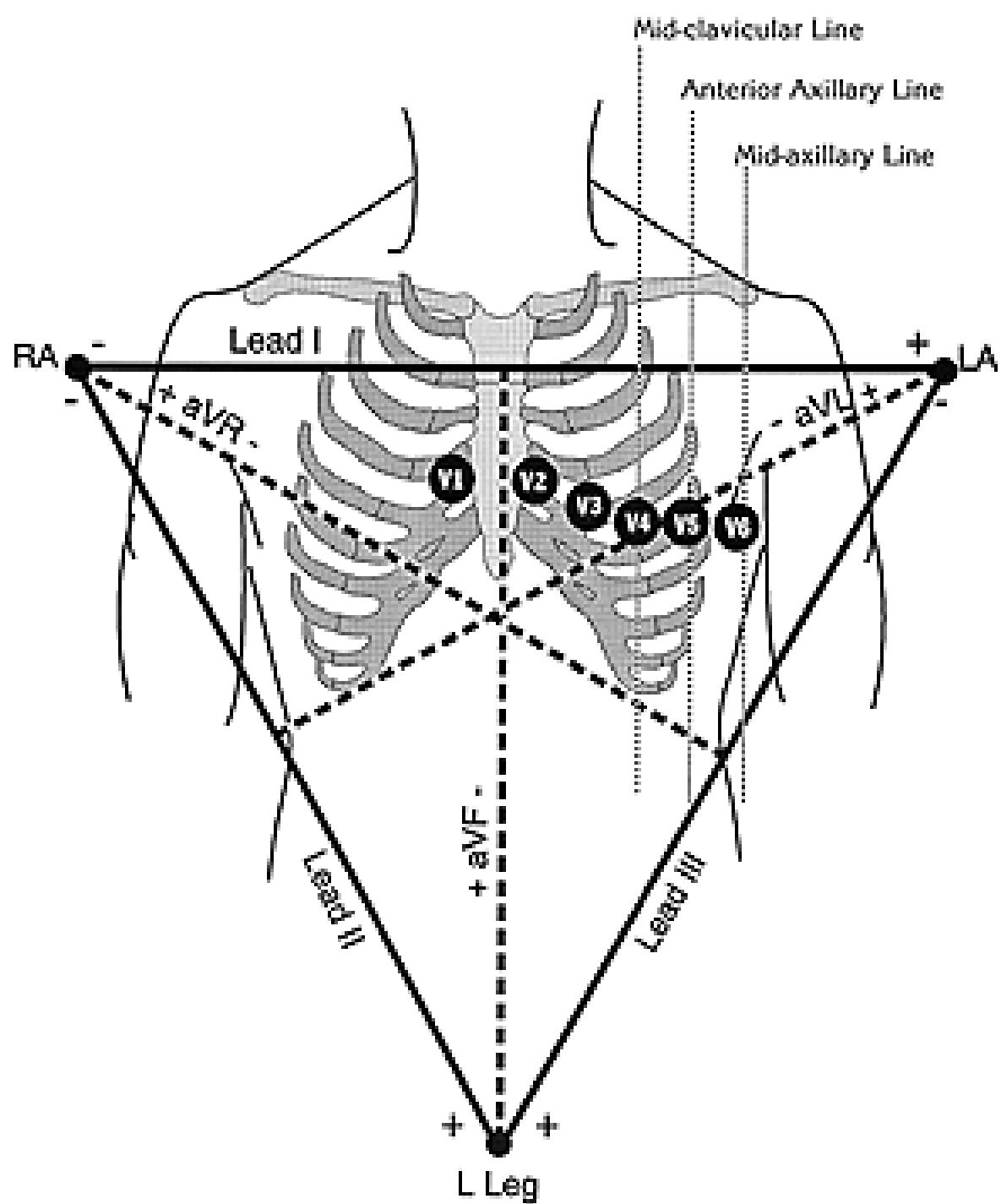


Fig 8. Typical ECG from lead II position



Six frontal plane ECG, some cases the waveform is positive and in other cases it is negative. The sign of the waveform depends upon the direction of electric dipole vector and polarity and position of the electrodes of the measuring instrument. For transverse plane measurement the negative terminal of ECG recorder is attached an indifferent electrode at the center point of three resistors connected RA, LL, LA, and other electrode is moved across the chest wall to the six different positions

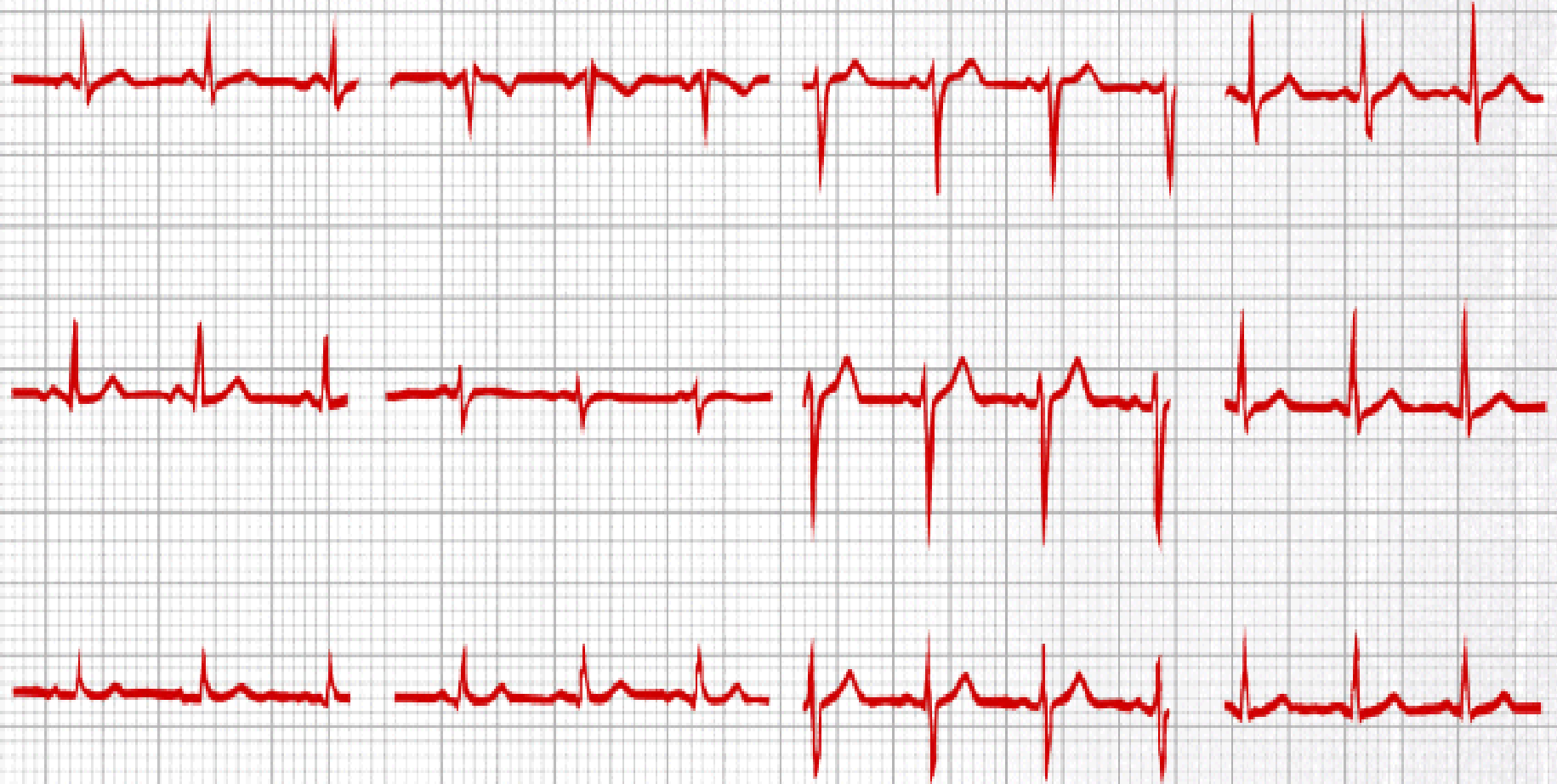

I II III

aVR aVL aVF

V1 V2 V3

V4 V5 V6



ELECTRICAL SIGNALS FROM THE BRAIN-ELECTROENCEPHALOGRAM

- The recording of the signals from the brain is called the electrocephalogram (EEG).
- Electrodes for recording the signals are often small discs of chloride silver. They are attached to the head at locations that depend upon the part of the brain to be studied. The international standard 10 -20 system of electrode location. Since asymmetrical activity is often an indication of brain disease, the right side signals are often compared to the left side signals.

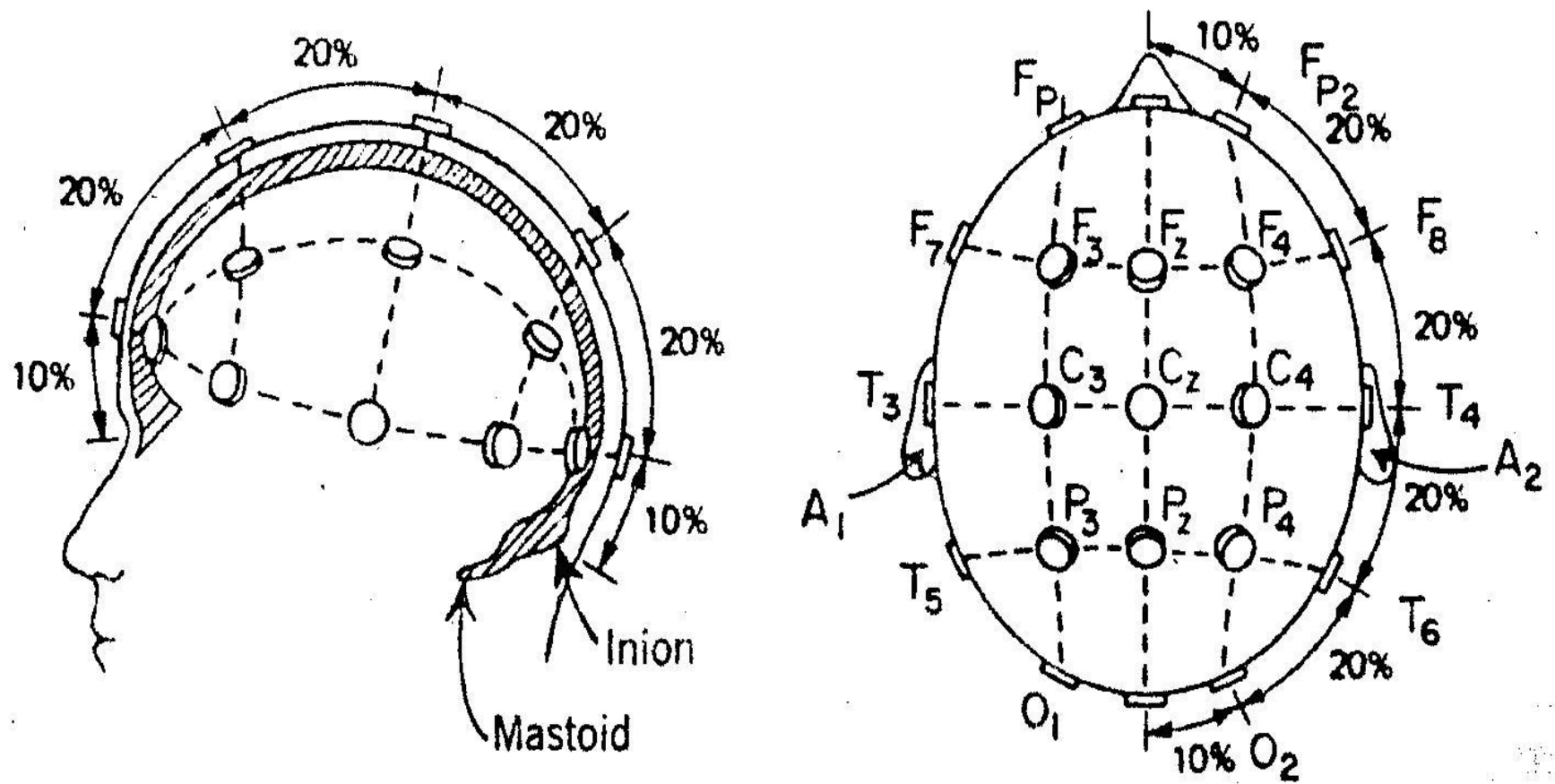


Fig 12 International standard 10 -20 system of electrode location for EEG •

dependent upon the mental activity of the object. For example, a relaxed person usually has an EEG signal composed primarily of frequencies from 8 to 13 Hz, or alpha wave. When a person is more alert a higher frequency range, the beta wave range (above 13 Hz), dominates the signal. The various frequency bands are as follows:

Delta (δ) or slow	0.5 to 3.5 Hz
Theta (θ) or intermediate slow	4 to 7 Hz
Alpha (α)	8 to 13 Hz
Beta (β), or fast	greater than 13 Hz

The EEG is used as an aid in the diagnosis of diseases involving the brain. It is most useful in the diagnosis of epilepsy and allows classification of epileptic seizures.

a-The EEG for a severe epileptic attack with loss of consciousness, called a grand mal seizure, shows fast high voltage spikes in all leads from the skull (Fig a).

b-The EEG for a less severe attack, called a petit mal seizure, shows up to 3 rounded wave per second followed or preceded by fast spikes (Fig b).

The EEG aids in confirming brain tumors since electrical activity is reduced in the region of a tumor.

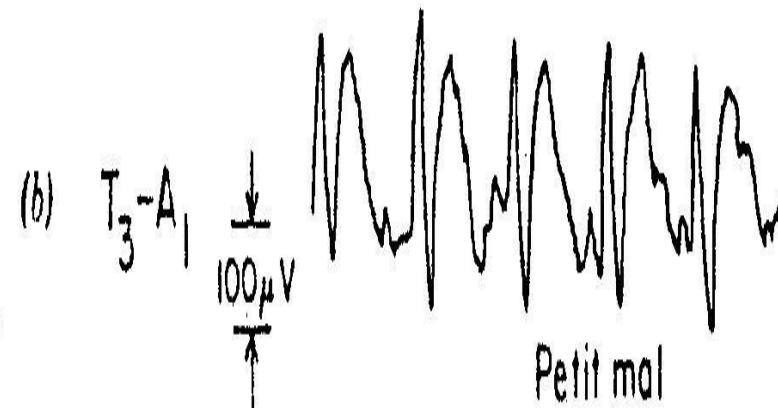
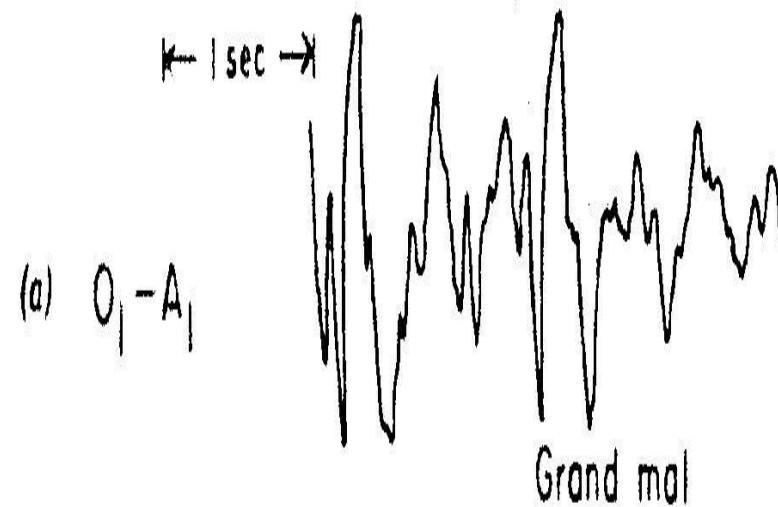
_The EEG is used as a monitor in surgery when the ECG cannot be used.

_It is useful in surgery for indicating the anesthesia level of the patient.

_Much research on sleep involves observing the EEG patterns for various stages of sleep.

drowsy, particularly with eyes closed, the frequencies from 8 to 13 Hz (α waves) dominate the EEG. The amplitude increases and the frequency decreases as a person moves from light sleep to deeper sleep.

b-EEG taken during sleep shows a high frequency pattern called paradoxical sleep or rapid eye movement (REM) sleep because the eyes move during this period. Paradoxical sleep appears to be associated with dreaming



Electroencephalograms for two types of epilepsy: (a) grand mal and (b)

MAGNETIC SIGNALS FROM THE HEART –MAGNETOCARDIOGRAM

- Since a flow of electrical charge produces a magnetic field, a magnetic field is produced by the current in the heart during depolarization and repolarization. MCG measures these very weak magnetic fields around the heart.
- The magnetic field around the heart is about 5×10^{-11} tesla (T), or about one-million of earth's magnetic field.
- $1 \text{ T} = 10^4 \text{ gauss}$

To measure fields of this size it is necessary to use magnetically shielded rooms and very sensitive magnetic field detectors

The MCG gives information about the heart without the use of electrodes touching the body. Since the MCG and ECG arise from the same charge movement they have similar features and can be compared.

